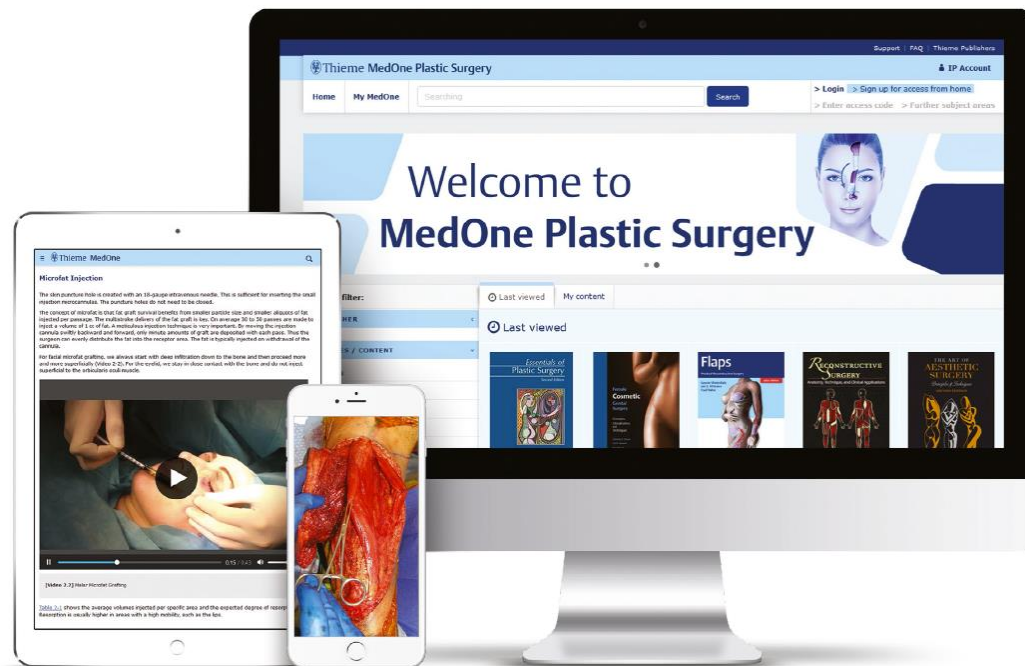

MedOne Plastic Surgery MedOne 整形外科資料庫

MedOne Plastic Surgery



關於MedOne Plastic Surgery

MedOne

MedOne整形外科資料庫是專為外科醫師開發的資料庫，讓外科醫師可專注於病患所需處置的狀況。資料庫匯集的內容皆是由此領域的專家所策劃的內容，代表外科醫生和住院醫生都可藉由此資料庫，提升他們的技能，並深入瞭解整形外科手術的各個細節。

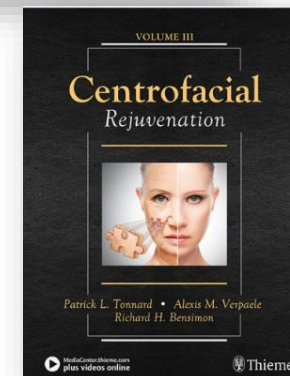




對於有經驗的專科醫生或住院醫生來說，MedOne是一個易於使用的平台，它結合了專家資訊及多媒體視覺資料，更是一個學習及教學的工具。

另外，MedOne讓繁忙的專科醫生和住院醫生不論在家、在工作或忙碌時，都可以簡易且有效率地快速獲得資訊！

收錄內容-電子書

MedOne

目前收錄超過120種有關整形重建和美容手術的重要電子書。無論你是在攻讀還是學習技術，都可以根據自己的需求使用資料庫內所提供的電子書的內容：展開圖片、觀看視頻、下載章節、個人化筆記、客製化閱讀清單和追蹤文章連結。



收錄內容-手術流程

MedOne

MedOne整形外科的“手術流程”為您準備了進入手術室所需的內容：透過step-by-step的方式讓您可以快速審視一個棘手的手術，或透過觀看不同的手術流程來了解手術的細節並藉由評估是否有其他更好的治療方法。

Hair transplantation

Surgical anatomy Technique Complications Videos

Source: Barrera A, Uebel C, ed. Hair Transplantation: The Art of Follicular Unit Micrografting and Minigrafting. 2nd Edition. Thieme; 2013. doi:10.1055/b-006-160945

Part 1 Fundamentals > Chapter 1 Anatomy and Physiology of Hair

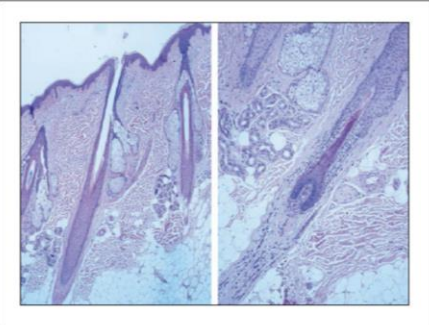
Chapter 1 Anatomy and Physiology of Hair

- Types of Hair
- Hair Follicle Development
- Hair Follicle Histology
- Follicular Unit Concept
- Hair Follicle Cycle
- Follicular Stem Cells
- Applied Anatomy: Alopecias Suitable for Hair Restoration Surgery
- Conclusion
- References

Anatomy and physiology of hair

Quick access

Types of Hair|Hair Follicle Development|Hair Follicle Histology|Follicular Unit Concept|Hair Follicle Cycle|Follicular Stem Cells|Anatomy: Alopecias Suitable for Hair Restoration Surgery|Conclusion|References



Francisco Jiménez, Alfonso Barrera, Carlos Oscar Uebel

Historically, hair has been a source of pride to humans and is a distinguishing feature that adorns as well as

Midface lift

Technique Complications Videos

Operative technique

From: *The Art of Aesthetic Surgery: Principles & Techniques*. (2010; 2nd Edition)

PART VII MIDFACIAL REJUVENATION > CHAPTER 37 Midface Recontouring > Operative Technique

Operative Technique


- Markings and Incisions
- Patient Positioning and Anesthesia
- Upper Lid Blepharoplasty: Exposure of the Lateral Orbital Rim and Temporal Fascia
- Midface Dissection
- Elevation and Fixation
- Excision of Lower Lid Skin
- Volume Replacement
- Brow Repositioning and Neck Lifting as a Component of Midface Rejuvenation
- Skin Resurfacing

Operative technique

Quick access

Markings and Incisions | Patient Positioning and Anesthesia | Upper Lid Blepharoplasty: Exposure of the Lateral Orbital Rim and Temporal Fascia | Midface Dissection | Elevation and Fixation | Excision of Lower Lid Skin | Volume Replacement | Brow Repositioning and Neck Lifting as a Component of Midface Rejuvenation | Skin Resurfacing

Markings and Incisions



Subciliary lower lid incision with lateral extension in a preexisting skin crease

收錄內容-向專家學習

MedOne

這些專家開創了您使用的技術和您尚未使用的尖端手術。當您在進行或學習他們擅長的手術時，為什麼不向大師學習呢？來自全球**43**名整形外科知名專家的資料包括視頻，解釋他們的技術、演示操作和討論併發症，因此您不需要周遊世界，就可以在您的導師中找到最好的。

The screenshot displays the 'Learn from the Masters' interface. On the left, there is a sidebar with filters for 'Sources / content' (E-Books, Procedures, E-Journals, Playlists, Images / Videos / Audio, Questions and Answers) and 'Subject areas'. The main area shows a grid of 20 expert profiles, each with a star icon. The profiles are: Al Aly, Alfonso Barrera, Arin Greene, Ashkan Ghavami, Bahman Guyuron, Christine Hamori, Christopher Salgado, Constantino Mendieta, Dean Toriumi, Dennis Hammond, Donald Lalonde, Elizabeth Hall-Findlay, Enrico Robotti, Fabio Nahas, and Foad Nahai. On the right, the 'Fu Chan Wei: Master videos' profile is shown, including a personal profile and a video player. The video player shows a surgical procedure with the caption: '[Video 1] Free ALT Flap for Circumferential Lower Leg Soft Tissue Defect Reconstruction. Source: Accompanying Videos. In: Pu L, Levine J, Wei F, ed. Reconstructive Surgery of the Lower Extremity. 1st Edition. Thieme, 2013. doi:10.1055/b-006-161008'.

Home

My MedOne

Searching in Learn from the Masters...

Search



> Login > Sign up for access from home

> Enter access code > Further subject areas

Your filters: **Learn from the Masters**

Please filter:

Content Collections

Sources / content

E-Books



Procedures



Learn from the Masters

E-Journals



Playlists



Images / Videos / Audio



Questions and Answers



Subject areas

Remove all filters



Al Aly



Alfonso Barrera



Arin Greene



Ashkan Ghavami



Bahman Guyuron



Christine Hamori



Christopher Salgado



Constantino Mendieta



Dean Toriumi



Dennis Hammond



Donald Lalonde



Elizabeth Hall-Findlay



Enrico Robotti



Fabio Nahas



Foad Nahai

Source: [Fu-Chan Wei](#). In: [Plastic Surgery: Masters Profiles](#). 1st Edition. Thieme; 2020.

- Fu-Chan Wei**
 - Personal profile
 - Master videos**
 - Microsurgery**
 - Flaps
 - Perforator flaps
 - Flaps
 - Transplantation

Fu-Chan Wei



Fu Chan Wei – Personal profile and master videos

Quick access

[Personal profile](#) | [Master videos](#)

Personal profile



Fu-Chan Wei, MD

Fu-Chan Wei, MD is a world-renowned plastic and reconstructive surgeon, and one of the most influential and innovative surgeons in the history of plastic surgery. The Taiwanese legend is the innovator of the osteoseptocutaneous fibula flap, which revolutionized the reconstruction of composite bone and soft tissue defects in the jaw and extremities. He has

收錄內容-多媒體資料

MedOne

在整形手術中，進行過程與結果都很重要。這就是為什麼平臺的圖像清楚地呈現了方法和結果。在多媒體頁面可方便地展開、下載或比較圖像，亦可透過資源外部連結瞭解更多資訊。MedOne 整形外科的手術和病例視頻為手術過程和結果提供珍貴的真實示例。

four filters: **Media**

Please filter: Audio/Image/Video Date Relevance

Sources / content

- E-Books
- Procedures
- Learn from the Masters
- E-Journals
- Playlists
- Images / Videos / Audio**
- Questions and Answers

Subject areas

Remove all filters

Images / Videos / Audio 74,730 results

MODALITY All

AUDIO/IMAGE/VIDEO All Image

Fig. 15.3 Hydrogel-coated pack with attached thread (Rapid Rhin...

Fig. 62.16 Relative-motion extension splint for middle finger I...

Fig. 40.1 Resurfacinglaser, burns inLaser resurfacing, burns inB...

Fig. 47-3 a-j This 34-year-old woman had a closed rhinoplasty 14 years prior and presented with a Pinocchio nose. A few years after her surgery, the tip overprojection deformity was already noticeable. However, the patient was afraid to undergo a second operation. She had a second operation 8 years after the first surgery and the asymmetry of the tip, exaggerated columellar length, and significant discrepancy between the dorsum and tip became more obvious. (a-c) The asymmetrical resection of the lower lateral cartilage...

Fig. 55-12 Rotationplasty for tumors of the ...

Fig. 12-4

Fig. 26.24 A malpositioned one-piece extended implant. (a) When...

Fig. 4-9 Large located on the result ...

Fig. 47-3 a-j Case analysis. This 34-year-old woman had a closed rhinoplasty 14 years prior and presented with a Pinocchio nose. A few years after her surgery, the tip overprojection deformity was already noticeable. However, the patient was afraid to undergo a second operation. She had a second operation 8 years after the first surgery and the asymmetry of the tip, exaggerated columellar length, and significant discrepancy between the dorsum and tip became more obvious. (a-c) The asymmetrical resection of the lower lateral cartilage...

收錄內容-訓練中心

MedOne

使用問題、答案和解釋的資料庫進行有效的學習。按解剖區域和手術分類超過1,000多個問題，自我測驗頁讓您標記要重複的問題、記住您的進度及將您的結果分析成易查看的統計資料，來解決了您的學習需求。

Back to overview

Basal cell carcinoma, squamous cell carcinoma, and melanoma Statistics of learning progress

157 / 1178

?
Question

!
Answer

i
Comment

Question
157


15.1. | Which one of the following statements is correct regarding basal cell carcinoma (BCC)?

- A. Incidence has recently plateaued.
- B. It more commonly affects females.
- C. It usually affects the trunk and limbs.
- D. The most commonly affected single site is the upper lip.
- E. It is the most common eyelid malignancy.

Correctly answered repeat

Next question >

Source:
Basal cell carcinoma, squamous cell carcinoma, and melanoma
From: Essentials of Plastic Surgery, Q&A Companion (1st Edition)
Short link: <https://medone-plasticsurgery.thieme.com/NO34R>



MedOne介面功能介紹

資料庫首頁

Thieme MedOne Plastic Surgery **檢索欄位**

Home My MedOne Search **個人筆記**

> Login > Sign up for access from home
> Enter access code > Further subject areas



NEW IN YOUR LICENSE PACKAGE

Oculoplastic Surgery

Third Edition
Brian Leatherbarrow

近期瀏覽

內容分享佈告欄

Please filter:

- Institutional favorites
- Last viewed


Sources / content

- E-Books **電子書**
- Procedures **手術流程**
- Learn from the Masters **向專家學習**
- E-Journals **電子期刊**
- Playlists
- Images / Videos / Audio **多媒體資料**
- Questions and Answers **訓練中心**


Subject areas

Remove all filters

Last viewed



Fu-Chan Wei



Al Aly

Plast

Procedures: Aesthetic surgery

>> Hair transplantation

Plastic surgery best sellers

Executive Editor Sue Hodgson

9 items
4 subscribers

UTSouthwestern
Medical Center

UTSW

Executive Editor Sue Hodgson

4 items
2 subscribers

Playlist

How to Create a MedOne Plastic

Playlist

MedOne Plastic Surgery - where to

FREE PLAYLIST

Playlist

Test Playlist

Operative Management of VASCULAR ANOMALIES

檢索功能

- 於檢索欄位輸入關鍵字時，系統會自動列出符合的最佳相關字及推薦的連結
- 您的檢索詞會呈現在上方，檢索結果面可以往下滾動。**PUBMED**相關結果會列在最下方
- 您可以在左方做進階篩選，每當您增加一篩選，該選項會呈現在上方，當然也可以移除
- 在電子書或期刊頁面中，題名下方的欄位可以進行檢索，而檢索結果會列在左方的“**Hits**”中，在內文中也會標示出來



檢索功能：於檢索欄位輸入關鍵字時，系統會自動列出符合的最佳相關字及推薦的連結

Editorial Board | Support | FAQ | Librarians | Thieme Publishers

Thieme MedOne Plastic Surgery Flysheet Demo Account

Home My MedOne > Login > Sign up for access from home
> Enter access code > Further subject areas

Playlist Collections

Content Collections



- Plast** Ethnic rhinoplasty
- Plast** Primary rhinoplasty
- Plast** Secondary rhinoplasty

Playlists

- Plast** Traynor
Day of Rhinoplasty - Closed technique
- Plast** Traynor
ISAPS Barcelona Rhinoplasty Course
- Plast** ISAPS
ISAPS SOS meeting Stuttgart
RHINOPLASTY

E-Journals

E-Books

-  Rohrich, Mohan, Afrooz
Dallas Rhinoplasty™ Meeting Video
Collection 2019
-  Rohrich, Ahmad
The Dallas Rhinoplasty and Dallas
Cosmetic Surgery Dissection Guide

> Show more

Chapter

- Plast** I Technical Considerations
Revision Rhinoplasty, 2007
- Plast** 1 Anatomy and Analysis
Revision Rhinoplasty, 2007

> Show more

Article

- Plast** Sonic Rhinoplasty: Innovative
Applications
Facial Plastic Surgery 2013; 29(02): 127 -
132
- Plast** Endoscopic Guided Rhinoplasty
Facial Plastic Surgery 2013; 29(02): 133 -
139

Search all

- rhinoplasty closed approach
- rhinoplasty endonasal approach
- rhinoplasty external approach
- rhinoplasty nasal airway
- rhinoplasty nasal tip

> Show more

Authors

Home

My MedOne

rhinoplasty

Search



> Login > Sign up for access from home

> Enter access code > Further subject areas

Your search: x rhinoplasty

Please filter:

Sources / content

E-Books



E-Journals



Playlists



Images / Videos / Audio



Questions and Answers



Subject areas

Remove all filters

Date

Relevance

E-Books 99 E-Books found with hits for "rhinoplasty"

Male Aesthetic Plastic Surgery, 1st Edition [2020]

Authors: S. Douglas Steinbrech



Steps for Male Rhinoplasty— Expert Technique

Steps for Male **Rhinoplasty** Expert Technique Male Aesthetic Plastic Surgery Part II Facial Surgery CHAPTER 18 Male **Rhinoplasty** Expert Technique Steps for Male **Rhinoplasty** Expert Technique Steps for Male **Rhinoplasty** Expert Technique A 31 year old man presented for open **rhinoplasty** He desired hump...

Male Rhinoplasty Considerations by Anatomical Regions


Male **Rhinoplasty** Considerations by Anatomical Regions Male Aesthetic Plastic Surgery Part II Facial Surgery CHAPTER 18 Male... **Rhinoplasty** Expert Technique Male **Rhinoplasty** Considerations by Anatomical Regions Male **Rhinoplasty** Considerations by Anatomical Regions Skin Soft Tissue The male nasal...

Steps for Male Rhinoplasty

Steps for Male **Rhinoplasty** Male Aesthetic Plastic Surgery Part II Facial Surgery CHAPTER 17 Male **Rhinoplasty** Steps for Male **Rhinoplasty** Steps for Male **Rhinoplasty** Open Approach The open septorhinoplasty approach can be considered the workhorse procedure for aesthetic **rhinoplasty** as it provides...

The Art of Aesthetic Surgery: Principles & Techniques, 3rd Edition [2020]

Authors: Foad Nahai et al.



Current edition

111.4.2 Rhinoplasty

111 4 2 **Rhinoplasty** The Art of Aesthetic Surgery Principles Techniques Part XIV Gender Affirming Surgery 111 Gender Affirming... Surgery Facial Surgery 111 4 Common Facial Feminization Procedures 111 4 2 **Rhinoplasty** 111 4 2 **Rhinoplasty** Male to female gender affirming **rhinoplasty** addresses the...

Rhinoplasty in Patients of African Descent

Rhinoplasty in Patients of African Descent The Art of Aesthetic Surgery Principles Techniques Part X **Rhinoplasty** 61 Primary **Rhinoplasty** 61 5 Preoperative Assessment 61 5 2 Facial Analysis **Rhinoplasty** in Patients of African Descent **Rhinoplasty** in Patients of African Descent Compared with the nasal...

63.5.3 Elevation of the Skin Flap for an External Rhinoplasty Approach

63 5 3 Elevation of the Skin Flap for an External **Rhinoplasty** Approach The Art of Aesthetic Surgery Principles Techniques Part X **Rhinoplasty** 63 Asian **Rhinoplasty** 63 5 Operative Technique 63 5 3 Elevation of the Skin Flap for an External... ... **Rhinoplasty** Approach 63 5 3 Elevation of the Skin Flap...

檢索功能：檢索結果頁面可以往下滾動。PUBMED相關結果會列在最下方

Editorial Board | Support | FAQ | Librarians | Thieme Publishers

Thieme MedOne Plastic Surgery
Flysheet Demo Account

Home
My MedOne

Search
?

[> Login](#)
[> Sign up for access from home](#)

[> Enter access code](#)
[> Further subject areas](#)

Your search: x rhinoplasty

	Date	Relevance
Please filter: Sources / content		
E-Books ?		<
E-Journals ?		<
Playlists ?		<
Images / Videos / Audio ?		<
Questions and Answers ?		<
Subject areas		
<input checked="" type="checkbox"/> Remove all filters		
E-Books 99 E-Books found with hits for "rhinoplasty"		<
Procedures 25 results for "rhinoplasty"		<
Learn from the Masters 14 results for "rhinoplasty"		<
Images / Videos / Audio 7,791 results for "rhinoplasty"		<
E-Journals 97 results for "rhinoplasty"		<
PubMed 11008 results for "rhinoplasty"		v
<p>Natural History of the Standardized Cosmesis and Health Nasal Outcomes Survey After Rhinoplasty. Authors: Kandathil CK / Saltychev M / Patel PN / Most SP Source: Laryngoscope. 2021 Jan;131(1):E116-E123</p>		
<p>Surgical Adjuncts to Rhinoplasty: An Algorithmic Approach. Authors: Peleman JR / Chung MT / Johnson J / Rayess H / Priest CR / Hojjat H / Mourad M / Carron MA / Vasconez HC Source: Aesthetic Plast Surg. 2020 Oct;44(5):1694-1704</p>		
<p>Analysis of the operative utilization of concurrent rhinoplasty and endoscopic sinus surgery.</p>		

檢索功能：可在左方做進階篩選，每當增加一篩選，該選項會呈現在上方，當然也可以移除

[Editorial Board](#) | [Support](#) | [FAQ](#) | [Librarians](#) | [Thieme Publishers](#)

Thieme MedOne Plastic Surgery Flysheet Demo Account

Home
My MedOne

Search
?

[> Login](#)
[> Sign up for access from home](#)

Your search: x rhinoplasty

Your filters: x E-Books

Please filter:

Sources / content

E-Books ?

E-Journals ?

Playlists ?

Images / Videos / Audio ?

Questions and Answers ?


Subject areas <

Remove all filters

E-Books 99 E-Books found with hits for "rhinoplasty" v

Male Aesthetic Plastic Surgery, 1st Edition [2020]

Authors: S. Douglas Steinbrech



Steps for Male Rhinoplasty— Expert Technique

Steps for Male **Rhinoplasty** Expert Technique Male Aesthetic Plastic Surgery Part II Facial Surgery CHAPTER 18 Male **Rhinoplasty** Expert Technique Steps for Male **Rhinoplasty** Expert Technique Steps for Male **Rhinoplasty** Expert Technique A 31 year old man presented for open **rhinoplasty** He desired hump...

Male Rhinoplasty Considerations by Anatomical Regions


Male **Rhinoplasty** Considerations by Anatomical Regions Male Aesthetic Plastic Surgery Part II Facial Surgery CHAPTER 18 Male... **Rhinoplasty** Expert Technique Male **Rhinoplasty** Considerations by Anatomical Regions Male **Rhinoplasty** Considerations by Anatomical Regions Skin Soft Tissue The male nasal...

Steps for Male Rhinoplasty

Steps for Male **Rhinoplasty** Male Aesthetic Plastic Surgery Part II Facial Surgery CHAPTER 17 Male **Rhinoplasty** Steps for Male **Rhinoplasty** Steps for Male **Rhinoplasty** Open Approach The open septorhinoplasty approach can be considered the workhorse procedure for aesthetic **rhinoplasty** as it provides...

The Art of Aesthetic Surgery: Principles & Techniques, 3rd Edition [2020]

Authors: Foad Nahai et al.



111.4.2 Rhinoplasty

111 4 2 **Rhinoplasty** The Art of Aesthetic Surgery Principles Techniques Part XIV Gender Affirming Surgery 111 Gender Affirming... Surgery Facial Surgery 111 4 Common Facial Feminization Procedures 111 4 2 **Rhinoplasty**

16

檢索功能：在電子書或期刊頁面中，題名下方的欄位可以進行檢索


Editorial Board | Support | FAQ | Librarians | Thieme Publishers

Thieme MedOne Plastic Surgery Flysheet Demo Account

Home My MedOne ? [> Login](#) [> Sign up for access from home](#)
[> Enter access code](#) [> Further subject areas](#)

[« Back to overview](#)

[S. Douglas Steinbrech](#)
Male Aesthetic Plastic Surgery



Source: In: [Steinbrech S](#), ed. 1st Edition. Thieme; 2020.
doi:10.1055/b-006-163729

Part I The Male-Oriented Office A ————— A

Part I The Male-Oriented Office

Quick access

CHAPTER 1 Marketing Aesthetic Procedures to Men|CHAPTER 2 Photography for the Male Aesthetic Patient|CHAPTER 3 Virtual Surgery

CHAPTER 1 Marketing Aesthetic Procedures to Men

Thomas F. La Vecchia and Douglas S. Steinbrech

Summary

As an increasing number of men are undergoing aesthetic procedures, aesthetic surgery centers need to familiarize themselves with proven techniques for marketing to the male client. This chapter covers general marketing techniques, such as brand positioning and content generation, as well as how to develop a revenue-generating social media presence.

Introduction

Content Images Hits

- Part I The Male-Oriented Office**
- Part II Facial Surgery
- Part III Body Surgery
- Part IV Injectables, Lasers, and

檢索功能：檢索結果會列在左方的“Hits”中，在內文中也會標示出來

Editorial Board | Support | FAQ | Librarians | Thieme Publishers

Thieme MedOne Plastic Surgery
Flysheet Demo Account

Home
My MedOne

Search
?


[> Login](#)
[> Sign up for access from home](#)
[> Enter access code](#)
[> Further subject areas](#)

« Back to overview

PDF
Share
∞

[S. Douglas Steinbrech](#)

Male Aesthetic Plastic Surgery



Source: In: [Steinbrech S](#), ed. 1st Edition. Thieme; 2020.
doi:10.1055/b-006-163729

Show videos

Q

Part II Facial Surgery > CHAPTER 18 Male Rhinoplasty: Expert Technique > Steps for Male Rhinoplasty— Expert Technique

Steps for Male Rhinoplasty— Expert Technique + Playlist

A 31-year-old man presented for open rhinoplasty. He desired hump reduction, deviation correction, tip elevation or refinement, and overall preservation of masculine contours and angles. After an internal examination, septoplasty and turbinoplasty were deemed also necessary.

To begin, we performed an open rhinoplasty followed by a component dorsal reduction and a caudal septal reduction. Septoplasty was performed to remove vomerine and nasomaxillary spicules on the left nostril. Next, “J”-shaped low-to-high osteotomies were performed. Appropriate caudal septal resection was performed. Tip suturing for tip shaping along with soft onlay grafts and alar contour grafts followed a columellar strut grafts. Finally, membranous caudal lining resection solidified the final tip position. Last, we performed bilateral turbinoplasties.

Source:

Steps for Male Rhinoplasty— Expert Technique. In: Steinbrech S, ed. Male Aesthetic Plastic Surgery. 1st Edition. Thieme; 2020. doi:10.1055/b-006-163729

Download bibliographical data (RIS)

Content
Images
Q Hits

Steps for Male Rhinoplasty— Expert Technique

Male Rhinoplasty Considerations by Anatomical Regions

檢視內文：利用滑鼠選取文字後，會自動跳出筆記視窗。登入My MedOne可自行定義筆記類別，填寫個人筆記，點選 “save” 按鍵，即可存檔。

Editorial Board | Support | FAQ | Librarians | Thieme Publishers

Thieme MedOne Plastic Surgery
Flysheet Demo Account


Home | My MedOne

[> Login](#) | [> Sign up for access from home](#)
[> Enter access code](#) | [> Further subject areas](#)

[« Back to overview](#) PDF | Share

[S. Douglas Steinbrech](#)

Male Aesthetic Plastic Surgery



Source: In: [Steinbrech S](#), ed. 1st Edition. Thieme; 2020.
doi:10.1055/b-006-163729

[Show videos](#)

Part II Facial Surgery > CHAPTER 18 Male Rhinoplasty: Expert Technique > Steps for Male Rhinoplasty— Expert Technique

Steps for Male Rhinoplasty— Expert Technique [+ Playlist](#)

A 31-year-old man presented for open rhinoplasty. He desired hump reduction, deviation correction, tip elevation or refinement, and overall preservation of masculine contours and angles. After an internal examination, septoplasty and turbinoplasty were deemed also necessary.

To begin, we performed an open rhinoplasty followed by a component dorsal reduction and a caudal septal reduction. Septoplasty was performed to remove vomerine and nasomaxillary spicules on the left nostril. Next, "J"-shaped low-to-high osteotomies were performed. Appropriate caudal septal resection was performed. Tip suturing for tip shaping along with soft onlay grafts and alar contour grafts followed a columellar strut grafts. Finally, membranous caudal lining resection solidified the final tip position. Last, we performed bilateral turbinoplasties.

Source:

 [Note](#) | [Copy](#) | [Search](#) | [Category](#)

Steps for Male Rhinoplasty— Expert Technique, 1st Edition. Thieme; 2020.
doi:10.1055/b-006-163729

Download bibliographical data (RIS)

檢視內文：可分章節下載PDF

Editorial Board | Support | FAQ | Librarians | Thieme Publishers

Thieme MedOne Plastic Surgery
Flysheet Demo Account

Home
My MedOne

Search


?

[> Login](#) > [Sign up for access from home](#)
[> Enter access code](#) > [Further subject areas](#)

[« Back to overview](#)

[S. Douglas Steinbrech](#)

Male Aesthetic Plastic Surgery



Source: In: [Steinbrech S](#), ed. 1st Edition. Thieme; 2020.
doi:10.1055/b-006-163729

Show videos

Part II Facial Surgery > CHAPTER 18 Male Rhinoplasty: Expert Technique

Steps for Male Rhinoplasty— Expert Technique

A 31-year-old man presented for open rhinoplasty. He desired overall preservation of masculine contours and angles. An open rhinoplasty was necessary.

To begin, we performed an open rhinoplasty followed by a rhinoplasty to remove vomerine and nasomaxillary spicules on the left nostril. Next, S-shaped low-to-high osteotomies were performed. Appropriate caudal septal resection was performed. Tip suturing for tip shaping along with soft onlay grafts and alar contour grafts followed a columellar strut grafts. Finally, membranous caudal lining resection solidified the final tip position. Last, we performed bilateral turbinoplasties.

Source:

Steps for Male Rhinoplasty— Expert Technique. In: Steinbrech S, ed. Male Aesthetic Plastic Surgery. 1st Edition. Thieme; 2020. doi:10.1055/b-006-163729

Download bibliographical data (RIS)

PDF

Share

Male Aesthetic Plastic Surgery (2020; 1st Edition)

Frontmatter (PDF)

- + Part I The Male-Oriented Office
- + Part II Facial Surgery
- + Part III Body Surgery
- + Part IV Injectables, Lasers, and Skincare

Glossary (PDF)

Index (PDF)

Home

My MedOne

Searching in E-Books

Search



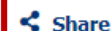> Login > Sign up for access from home

> Enter access code > Further subject areas

<< Back to overview



PDF



Share



S. Douglas Steinbrech

Male Aesthetic Plastic Surgery



Source: In: [Steinbrech S](#), ed. 1st Edition. Thieme; 2020.
doi:10.1055/b-006-163729

Show videos

Content

Images

Hits

Steps for Male Rhinoplasty— Expert Technique

Male Rhinoplasty Considerations by Anatomical Regions

rhinoplasty



Part II Facial Surgery > CHAPTER 18 Male Rhinoplasty: Expert Technique > Steps for Male



Rhinoplasty— Expert Technique

Steps for Male Rhinoplasty— Expert Technique [+ Playlist](#)

A 31-year-old man presented for open **rhinoplasty**. He desired hump reduction, deviation correction, tip elevation or refinement, and overall preservation of masculine contours and angles. After an internal examination, septoplasty and turbinoplasty were deemed also necessary.

To begin, we performed an open **rhinoplasty** followed by a component dorsal reduction and a caudal septal reduction. Septoplasty was performed to remove vomerine and nasomaxillary spicules on the left nostril. Next, "J"-shaped low-to-high osteotomies were performed. Appropriate caudal septal resection was performed. Tip suturing for tip shaping along with soft onlay grafts and alar contour grafts followed a columellar strut grafts. Finally, membranous caudal lining resection solidified the final tip position. Last, we performed bilateral turbinoplasties.

Source:

Steps for Male Rhinoplasty— Expert Technique. In: Steinbrech S, ed. Male Aesthetic Plastic Surgery. 1st Edition. Thieme; 2020.
doi:10.1055/b-006-163729

Download bibliographical data (RIS)

閱讀模式：隱藏所有按鈕或選項，自定義字體大小


Thieme MedOne PL

Home My MedOne

« Back to overview

S. Douglas Steinbrech

Male Aesthetic Plas



Source: In: [Steinbrech S, et al.](#) 1st Edition. Thieme; 2020.
doi:10.1055/b-006-163729

Show videos

Content Images Hits

Steps for Male Rhinoplasty— Ex
Technique

Male Rhinoplasty Consideration:
Anatomical Regions

S. Douglas Steinbrech

Male Aesthetic Plastic Surgery

Part II Facial Surgery > CHAPTER 4 Techniques for Forehead Rejuvenation

Part II Facial Surgery

CHAPTER 4 Techniques for Forehead Rejuvenation

Ximena Pinell and Foad Nahai

Evaluation of the Aging Forehead and Brow|Goals of Forehead Rejuvenation|Options for Forehead Rejuvenation|Coronal Brow Lift|Endoscopic Brow Lift|Lateral Temporal Brow Lift|Transpalpebral Corrugator and Procerus Excision|Transpalpebral Browpexy|Direct Excision|Neurotoxins|Bulleted Steps|Suggested Readings

Summary

Aging in the upper face can create a tired, unhappy, or even angry appearance. Surgical procedures to rejuvenate the forehead and brow can be very impactful to a person's overall expression and are thus very rewarding for the patient and surgeon alike. This chapter reviews important features to consider when assessing the aging brow and highlights key differences encountered in the male patient. Various surgical options are presented. Advantages and drawbacks for each approach are described, as are technical points to executing the surgery.

Evaluation of the Aging Forehead and Brow

Facial rejuvenation requires a comprehensive approach to the structures of the face and their interactions. No one feature or area should be considered in isolation, even if patients present with a single area of concern. The contribution of brow ptosis to an aged facial appearance is frequently overlooked but must be considered to achieve a natural, balanced, and aesthetic result.

In evaluating the aging forehead and brow, important features to consider are as follows:

- ▶ Brow position and shape.
- ▶ Orbital crowding.

FAQ | Librarians | Thieme Publishers

Flysheet Demo Account

sign up for access from home

Access code > Further subject areas

PDF Share ∞

Search

A

Playlist

tip elevation or refinement, and
d turbinoplasty were deemed also

septal reduction. Septoplasty was
o-high osteotomies were
h soft onlay grafts and alar
d the final tip position. Last, we

1st Edition. Thieme; 2020.

比較功能：可以跨資源進行圖片的比較

Editorial Board | Support | FAQ | Librarians | Thieme Publishers

Thieme MedOne Plastic Surgery Flysheet Demo Account

Home My MedOne ? > Login > Sign up for access from home
> Enter access code > Further subject areas

Your search: x rhinoplasty

Your filters: x Media


Please filter: Audio/Image/Video Date Relevance


Sources / content Show selection Please select


- E-Books ?
- E-Journals ?
- Playlists ?
- Images / Videos / Audio** ?
- Questions and Answers ?


Subject areas <

Remove all filters










電子書

- 於電子書頁面的檢索欄位輸入關鍵字，符合的相關結果會列在左方“Hits”中。點選任一標題後則可查看在內文中的檢索結果
- 可點選Images功能鍵查看電子書各章節中的圖片。滑鼠停留在縮圖上就可看到該圖的詳細資訊。點選進去可看到全尺寸的圖片
- Content功能鍵讓您可瀏覽電子書的各個章節



電子書：可依主題、書名和作者進行瀏覽，依字順或出版時間排序

Editorial Board | Support | FAQ | Librarians | Thieme Publishers

Thieme MedOne Plastic Surgery Flysheet Demo Account

Home My MedOne ? > Login > Sign up for access from home
> Enter access code > Further subject areas

Your filters: X E-Books

Please filter: Sub-Topic Title Author / Editor A - Z Publication date

Sources / content ▾


- E-Books** ?
- Procedures ?
- Learn from the Masters
- E-Journals ?
- Playlists ?
- Images / Videos / Audio ?
- Questions and Answers ?

Subject areas <


Remove all filters

X


- Aesthetic
- Anatomy
- Breast
- Facial
- Flaps and microsurgery
- General
- Hand and wrist
- Oculoplastic
- Pediatric




Reconstructive Breast Surgery
Solving Complications and Avoiding Unfavorable Results
Edited by Seth Thaler, Zubin J Panthaki
Thieme




Cosmetics & Techniques
Elizabeth J. Hall-Fordley
Thieme



AESTHETIC MEDICINE
IMPROVING YOUR PRACTICE
Thieme



Principles & Techniques
Lee L-Q, Ivy
Thieme



Thieme

Home

My MedOne

Searching in E-Books

Search



> Login > Sign up for access from home

> Enter access code > Further subject areas

Your filters: ✕ E-Books ✕ Facial

Please filter:

Facial

Title

Author / Editor

A - Z

Publication date

Sources / content

E-Books

Playlists

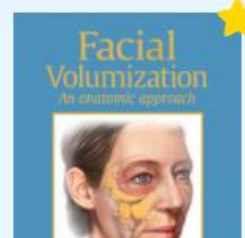
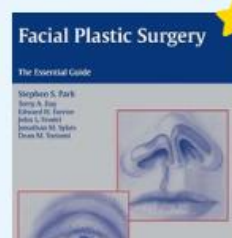
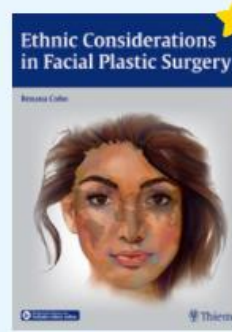



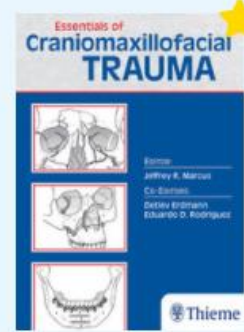



Images / Videos / Audio

Questions and Answers

Subject areas

Remove all filters

Search for title or editor



Home

My MedOne

Searching in E-Books

Search



> Login > Sign up for access from home

> Enter access code > Further subject areas

Your filters: **E-Books**

Please filter:

Sub-Topic

Title

Author / Editor

A - Z

Publication date

Sources / content

Search for title or editor

E-Books

Procedures

Learn from the Masters

E-Journals

Playlists

Images / Videos / Audio

Questions and Answers

Subject areas

Derm Dermatology and Venerology

Misc Miscellaneous

Nsurg Neurosurgery

Oph Ophthalmology


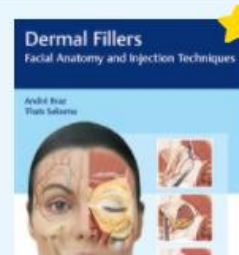

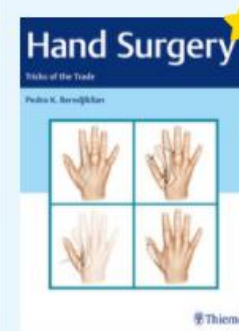
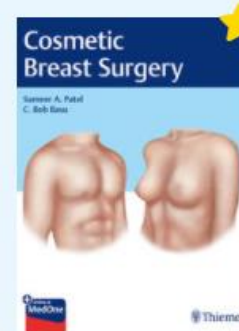
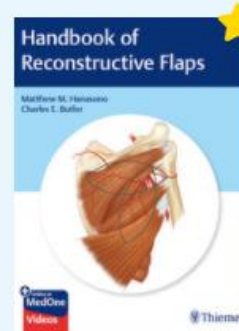
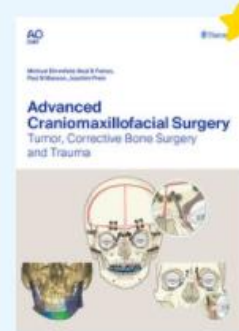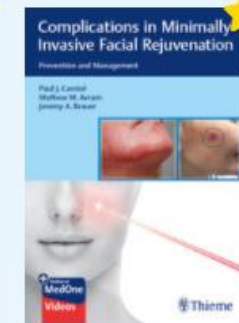

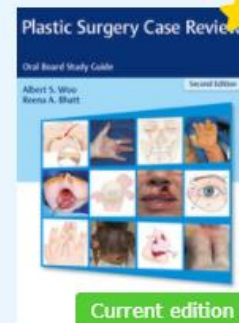
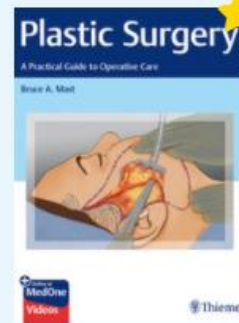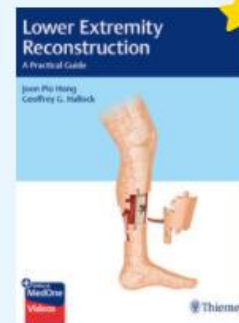
Ortho Orthopedics and traumatology

ORL Otolaryngology

Plast Plastic surgery

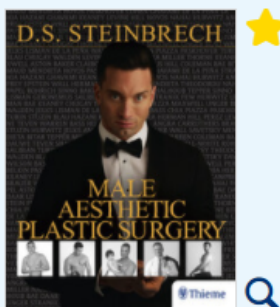
Rad Radiology

Remove all filters



[S. Douglas Steinbrech](#)

Male Aesthetic Plastic Surgery



Source: In: [Steinbrech S](#), ed. 1st Edition. Thieme; 2020.
doi:10.1055/b-006-163729

[Show videos](#)[Content](#) [Images](#) [Hits](#)

Steps for Male Rhinoplasty— Expert Technique

Male Rhinoplasty Considerations by Anatomical Regions

Steps for Male Rhinoplasty

CHAPTER 18 Male Rhinoplasty: Expert Technique

CHAPTER 17 Male Rhinoplasty

Technological Advances in Virtual Surgery

Management of Complications

CHAPTER 3 Virtual Surgery

CHAPTER 12 Chin Augmentation

Trends in Male Preferences for Aesthetics Surgery



Part I The Male-Oriented Office



Part I The Male-Oriented Office [+ Playlist](#)

Quick access

[CHAPTER 1 Marketing Aesthetic Procedures to Men](#)|[CHAPTER 2 Photography for the Male Aesthetic Patient](#)|[CHAPTER 3 Virtual Surgery](#)

CHAPTER 1 Marketing Aesthetic Procedures to Men

Thomas F. La Vecchia and Douglas S. Steinbrech

Summary

As an increasing number of men are undergoing aesthetic procedures, aesthetic surgery centers need to familiarize themselves with proven techniques for marketing to the male client. This chapter covers general marketing techniques, such as brand positioning and content generation, as well as how to develop a revenue-generating social media presence.

Introduction

X Factor Media was approached by Dr. Douglas S. Steinbrech in late 2013 with a new initiative. He wanted to roll out a website dedicated to male aesthetic surgery. At the time, we were a bit skeptical. Our research showed that men only constituted for roughly 9% of all aesthetic procedures in 2012. We were tasked with creating a website or an online resource (more or less). Male Plastic Surgery New York was born (www.MalePlasticSurgeryNewYork.com) ([Fig. 1.1](#)).

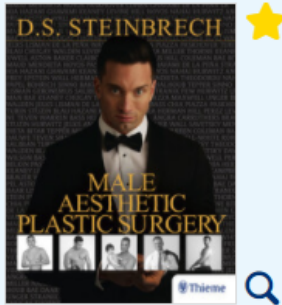
Our Approach: Build the Platform

X Factor Media started the campaign with reviewing the top procedures for men. According to the American Society for Aesthetic Plastic Surgery (ASAPS),¹ they are:

- ▶ Liposuction.
- ▶ Gynecomastia (removal of breast tissue).
- ▶ Eyelid surgery.
- ▶ **Rhinoplasty.**
- ▶ Facelift.

S. Douglas Steinbrech

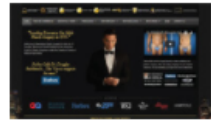
Male Aesthetic Plastic Surgery



Source: In: [Steinbrech S](#), ed. 1st Edition. Thieme; 2020. doi:10.1055/b-006-163729

Show videos

Content **Images** Hits



Male Aesthetic Plastic Surgery 2020; 1st Edition

Fig. 1-3. Infographic featured on maleplasticsurgerynewyork.com that was eventually picked up by numerous media outlets. (This image is provided courtesy of Male Plastic Surgery New York.)



rhinoplasty

Part I The Male-Oriented Office

Part I The Male-Oriented Office [+ Playlist](#)

Quick access

CHAPTER 1 Marketing Aesthetic Procedures to Men|CHAPTER 2 Photography for the Male Aesthetic Patient|CHAPTER 3 Virtual Surgery

CHAPTER 1 Marketing Aesthetic Procedures to Men

Thomas F. La Vecchia and Douglas S. Steinbrech

Summary

As an increasing number of men are undergoing aesthetic procedures, aesthetic surgery centers need to familiarize themselves with proven techniques for marketing to the male client. This chapter covers general marketing techniques, such as brand positioning and content generation, as well as how to develop a revenue-generating social media presence.

Introduction

X Factor Media was approached by Dr. Douglas S. Steinbrech in late 2013 with a new initiative. He wanted to roll out a website dedicated to male aesthetic surgery. At the time, we were a bit skeptical. Our research showed that men only constituted for roughly 9% of all aesthetic procedures in 2012. We were tasked with creating a website or an online resource (more or less). Male Plastic Surgery New York (www.MalePlasticSurgeryNewYork.com) (**Fig. 1.1**).

Build the Platform

The campaign with reviewing the top procedures for men. According to the American Society for Aesthetic Plastic Surgery, the top 10 most common procedures performed on men in 2012 were:

(removal of breast tissue).

[S. Douglas Steinbrech](#)

Male Aesthetic Plastic Surgery



Source: In: [Steinbrech S](#), ed. 1st Edition. Thieme; 2020.
doi:10.1055/b-006-163729

[Show videos](#)[Content](#)[Images](#)[Hits](#)

Part I The Male-Oriented Office

+ CHAPTER 1 Marketing Aesthetic Procedures to Men

- CHAPTER 2 Photography for the Male Aesthetic Patient

Introduction

Putting Photography into a Practice

Conclusion

Suggested Readings

+ CHAPTER 3 Virtual Surgery

+ Part II Facial Surgery

+ Part III Body Surgery

+ Part IV Injectables, Lasers, and Skincare

Glossary

+ Frontmatter



Part I The Male-Oriented Office



Part I The Male-Oriented Office [+ Playlist](#)

Quick access

[CHAPTER 1 Marketing Aesthetic Procedures to Men](#)|[CHAPTER 2 Photography for the Male Aesthetic Patient](#)|[CHAPTER 3 Virtual Surgery](#)

CHAPTER 1 Marketing Aesthetic Procedures to Men

Thomas F. La Vecchia and Douglas S. Steinbrech

Summary

As an increasing number of men are undergoing aesthetic procedures, aesthetic surgery centers need to familiarize themselves with proven techniques for marketing to the male client. This chapter covers general marketing techniques, such as brand positioning and content generation, as well as how to develop a revenue-generating social media presence.

Introduction

X Factor Media was approached by Dr. Douglas S. Steinbrech in late 2013 with a new initiative. He wanted to roll out a website dedicated to male aesthetic surgery. At the time, we were a bit skeptical. Our research showed that men only constituted for roughly 9% of all aesthetic procedures in 2012. We were tasked with creating a website or an online resource (more or less). Male Plastic Surgery New York was born (www.MalePlasticSurgeryNewYork.com) ([Fig. 1.1](#)).

Our Approach: Build the Platform

X Factor Media started the campaign with reviewing the top procedures for men. According to the American Society for Aesthetic Plastic Surgery (ASAPS),¹ they are:

- ▶ Liposuction.
- ▶ Gynecomastia (removal of breast tissue).
- ▶ Eyelid surgery.
- ▶ **Rhinoplasty.**
- ▶ Facelift.

電子期刊

- 當點選一本期刊，您會看到最新一期的內容。若想瀏覽過期卷期，則可點選**Archive**功能鍵
- 當在瀏覽過期卷期時，您可進一步以年代、卷期號、文章主題和文章類型作篩選。
- 在內文上方的欄位可進行快速檢索。檢索後點選左方的“**Hits**”則可看到結果，也會標示於內文中
- 點選右上方的**PDF**功能鍵則可下載或列印
- 點選右上方的眼鏡圖示則可切換成電子書閱讀畫面，文字可放大或縮小檢視



電子期刊：可依刊名、年、卷、期、文章主題和類型篩選

Editorial Board | Support | FAQ | Librarians | Thieme Publishers

Thieme MedOne Plastic Surgery Flysheet Demo Account

Home My MedOne ?

> Login > Sign up for access from home
> Enter access code > Further subject areas

Your filters: X E-Journals


Please filter: Title Year Issue Article subject Article type Name Publication date

Sources / content Search for title

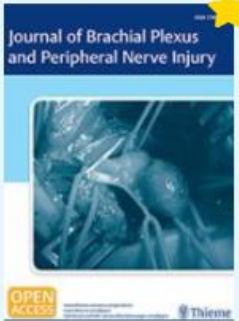
- E-Books ?
- Procedures ?
- Learn from the Masters
- E-Journals** ?
- Playlists ?
- Images / Videos / Audio ?
- Questions and answers ?

Subject areas


Remove all filters




Archive




Archive




Archive




Archive




Archive





Home My MedOne ? [> Login](#) [> Sign up for access from home](#)
[> Enter access code](#) [> Further subject areas](#)

Your filters: ✕ E-Journals

Please filter:	Title	Year	Issue	Article subject	Article type	Name	Publication date
Sources / content ▼ <input type="button" value="Show selection"/> <input type="checkbox"/> Please select ✕							
E-Books ?							
Procedures ?							
Learn from the Masters							
E-Journals ?							
Playlists ?							
Images / Videos / Audio ?							
Questions and Answers ?							
Subject areas <							
<input checked="" type="checkbox"/> Remove all filters							
<input type="checkbox"/> Book review		<input type="checkbox"/> Case report		<input type="checkbox"/> Letter to the editor, Publisher's note, Obituary, Foreword		<input type="checkbox"/> Editorial	
<input type="checkbox"/> Education		<input type="checkbox"/> Erratum, Correction		<input type="checkbox"/> Guideline		<input type="checkbox"/> Report, Paper	
<input type="checkbox"/> Review article		<input type="checkbox"/> Original paper		<input type="checkbox"/> Society		<input type="checkbox"/> Miscellaneous	
							
<input type="button" value="Archive"/>		<input type="button" value="Archive"/>					
No additional entries available							

電子期刊：點選一本期刊，您會看到最新一期的內容

[Editorial Board](#) | [Support](#) | [FAQ](#) | [Librarians](#) | [Thieme Publishers](#)

Thieme MedOne Plastic Surgery

[Flysheet Demo Account](#)

[Home](#) | [My MedOne](#)

Search
?

[> Login](#) | [> Sign up for access from home](#)
[> Enter access code](#) | [> Further subject areas](#)

« Back to overview
Share

Journal of Reconstructive Microsurgery 02/2021

Journal of Reconstructive Microsurgery 02/2021

Archive

Content | Images | Hits

- + Review Article
- + Original Article

Q

Review Article

Anatomy, Exposure, and Preparation of Recipient Vessels in Microsurgical Head and Neck Reconstruction
 Xu, Hope; Jazayeri, Leila; Matros, Evan; Henderson, Peter W.

Original Article

Perforator Mapping Practice for Deep Inferior Epigastric Artery Perforator Flap Reconstructions: A Survey of the Benelux Region
 Boer, Vivian B.; van Wingerden, Jan J.; Wever, Carolien F.; Beets, Michiel R.; Verhaegen, Pauline D.; Hamdi, Moustapha

Novel Porcine Kidney-Based Microsurgery Training Model for Developing Basic to Advanced Microsurgical Skills
 dos Reis, Jose Maciel Caldas; Teixeira, Renan Kleber Costa; Santos, Deivid Ramos dos; Calvo, Faustino Chaves; de Araújo, Nayara Pontes; de Corrêa Junior, Wender Jesus Pena; Pimentel, Antonio Leonardo Jatahi Cavalcanti; de Barros, Rui Sergio Monteiro

[Home](#)[My MedOne](#)

Searching in E-Journals

Search

[> Login](#) [> Sign up for access from home](#)[> Enter access code](#) [> Further subject areas](#)Your filters: [x E-Journals](#) [x Journal of Reconstructive Microsurgery](#)

Please filter:

Journal of Reconstructiv...

Year

Issue

Article subject

Article type

Sources / content

E-Journals

Playlists

Images / Videos / Audio

Questions and Answers

Subject areas

 Remove all filters

Current edition

eFirst



02/2021



eFirst

All issues



01/2021



09/2020



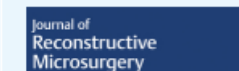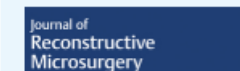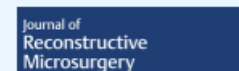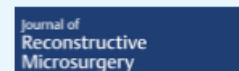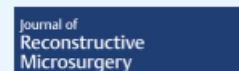08/2020



07/2020



06/2020



[Home](#)[My MedOne](#)

Searching in E-Journals

Search

[> Login](#) [> Sign up for access from home](#)[> Enter access code](#) [> Further subject areas](#)[« Back to overview](#)

Share



Journal of Reconstructive Microsurgery 02/2021

Journal of Reconstructive
Microsurgery 02/2021

Archive

[Content](#) [Images](#) [Hits](#)

Review Article

Anatomy, Exposure, and Preparation of Recipient Vessels in Microsurgical Head and Neck Reconstruction

Anatomy

Vessel Selection

Exposure Techniques

Anterior Triangle (External Carotid Branches, Internal Jugular System, and External Jugular System)

Submandibular (Facial Artery and Facial Vein)

Search within this E-Journal



Journal of Reconstructive Microsurgery 2021; 37(02): 097 - 110

DOI: 10.1055/s-0040-1715644

Review Article

Xu, Hope¹; Jazayeri, Leila²; Matros, Evan³; Henderson, Peter W.¹Anatomy, Exposure, and Preparation of Recipient Vessels in Microsurgical Head and Neck Reconstruction [+ Playlist](#)¹ Division of Plastic and Reconstructive Surgery, Department of Surgery, Icahn School of Medicine at Mount Sinai, New York, New York² Department of Plastic Surgery, Kaiser Permanente, San Leandro Medical Center, San Leandro, California³ Plastic and Reconstructive Surgical Service, Memorial Sloan Kettering Cancer Center, New York, New York

Quick access

Anatomy|Vessel Selection|Exposure Techniques|Anterior Triangle (External Carotid Branches, Internal Jugular System, and External Jugular System)|Submandibular (Facial Artery and Facial Vein)|Intraoral (Facial Artery and Facial Vein)|Posterior Triangle (Transverse Cervical Artery and Transverse Cervical Vein)|Preauricular (Superficial Temporal Artery and Superficial Temporal Vein)|Chest (Internal Mammary Artery and Internal Mammary Vein[s])|Arm/Infraclavicular Region (Cephalic Vein)|Conclusion|References

Abstract

Successful microvascular reconstruction of head and neck defects requires the ability to safely identify, isolate, and utilize recipient vessels. To date, however, a comprehensive review of the anatomy and techniques relevant to the available anatomic regions has not been undertaken. This review covers the relevant clinical anatomy of the anterior triangle, posterior triangle, submandibular region, intraoral region, preauricular region, chest, and arm, taking particular care to highlight the structures that are crucial to identify while performing each dissection. Finally, a step-by-step technique for safely dissecting the recipient

8 Yu P. The transverse cervical vessels as recipient vessels for previously treated head and neck cancer patients. *Plast Reconstr Surg* 2005; 115 (05) 1253-1258

Search in: [PubMed](#) [Google Scholar](#)

9 Venkatesh V, Fracol M, Turin S, Ellis M, Alghoul M. Utilization of intraparotid segments of superficial temporal vessels for head and scalp free flap microanastomosis: a clinical, histological, and cadaveric study. *J Reconstr Microsurg* 2020; 36 (04) 253-260

Search in: [PubMed](#) [Google Scholar](#)

10 Shankhdhar VK, Yadav PS, Dushyant J, Seetharaman SS, Chinmay W. Cephalic vein: saviour in the microsurgical reconstruction of breast and head and neck cancers. *Indian J Plast Surg* 2012; 45 (03) 485-493

Search in: [PubMed](#) [Google Scholar](#)

11 Agostini T, Agostini V. Cephalic vein transposition in head and neck microsurgery: advantages of a modified step-wise (closed) technique. *J Plast Reconstr Aesthet Surg* 2009; 62 (05) 625

Search in: [PubMed](#) [Google Scholar](#)

Address for correspondence

Peter W. Henderson, MD, MBA

Division of Plastic and Reconstructive Surgery, Department of Surgery, Icahn School of Medicine at Mount Sinai
10 Union Square East, Suite 2L, New York, NY 10003

peter.henderson@mountsinai.org

Keywords

head and neck reconstruction – microsurgery – recipient vessels

Source:

Xu H, Jazayeri L, Matros E et al. Anatomy, Exposure, and Preparation of Recipient Vessels in Microsurgical Head and Neck Reconstruction. *Journal of Reconstructive Microsurgery* 2021; 37(02): 097 - 110. doi:10.1055/s-0040-1715644

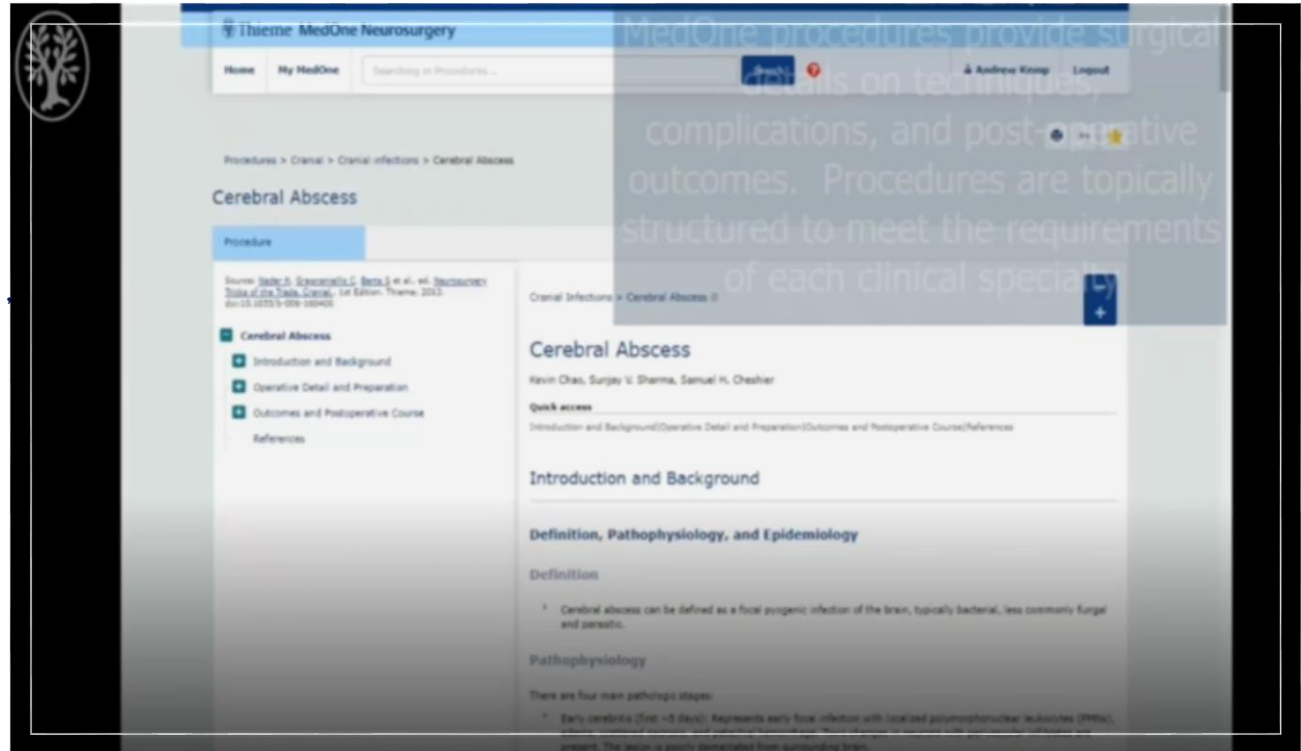
[Download bibliographical data \(RIS\)](#)

[Next >](#)

Short link: <https://medone-plasticsurgery.thieme.com/2T2Q6>

手術流程

- 於首頁下方點選**Procedures**功能鍵進入手術流程頁面，接著點選欲了解的主題，再點選手術主題
- 點選進欲瀏覽的手術項目後您會先看到概要，每一節都可以展開做深入的檢視
- 可點選右上方**Print**圖示將手術流程列印出來
- 當您登入個人**MedOne**帳號時，可點選右上方黃色星號將該手術流程加入目錄清單或資料庫首頁畫面



手術流程

Home

My MedOne

Searching in Procedures...

Search



> Login > Sign up for access from home

> Enter access code > Further subject areas

Your filters: ✕ Procedures

<p>Please filter:</p> <p>Sources / content ▾</p> <ul style="list-style-type: none"> E-Books ? Procedures ? Learn from the Masters E-Journals ? Playlists ? Images / Videos / Audio ? Questions and Answers ? <p>Subject areas <</p> <p><input checked="" type="checkbox"/> Remove all filters</p>	<p>Content Collections ▾</p> <div style="display: flex; justify-content: space-around;"> <div style="border: 1px solid #ccc; padding: 5px; width: 45%;"> <p>Plast ★</p> <p>Procedures: Aesthetic surgery</p> </div> <div style="border: 1px solid #ccc; padding: 5px; width: 45%;"> <p>Plast ★</p> <p>Procedures: Reconstructive surgery</p> </div> </div> <p style="text-align: center; background-color: #e0f0ff; padding: 5px;">No additional entries available</p>
---	--

Home

My MedOne

Searching in Procedures...

Search



> Login > Sign up for access from home

> Enter access code > Further subject areas

Your filters: ✕ Procedures: Aesthetic surgery ✕ Procedures

Please filter:

Sources / content

Procedures

Playlists

Questions and Answers

Subject areas

Remove all filters

Procedures: Aesthetic surgery

Plast

Procedures: Aesthetic surgery

Face

Breast

Body

Brachioplasty

Abdominoplasty

Buttocks

Lower extremity

Female genital surgery

Massive weight loss procedures

Liposuction

Fat grafting

Abdominoplasty

Surgical anatomy

Technique

Complications

Videos

Surgical steps

Source: [Surgical Anatomy](#). In: [Aly A, Nahas F](#), ed. [The Art of Body Contouring: A Comprehensive Approach](#). 1st Edition. Thieme; 2017. doi:10.1055/b-005-145240

Surgical Anatomy

LANDMARKS AND ANATOMIC UNITS OF THE ABDOMEN

SKIN AND SUBCUTANEOUS ANATOMY

BLOOD SUPPLY

SENSITIVE INNERVATION

LYMPHATIC SYSTEM

MYOAPONEUROTIC ANATOMY

THE UMBILICUS

CHAPTER 1 Anatomic and Physiologic Changes of the Abdominal Wall > Surgical Anatomy



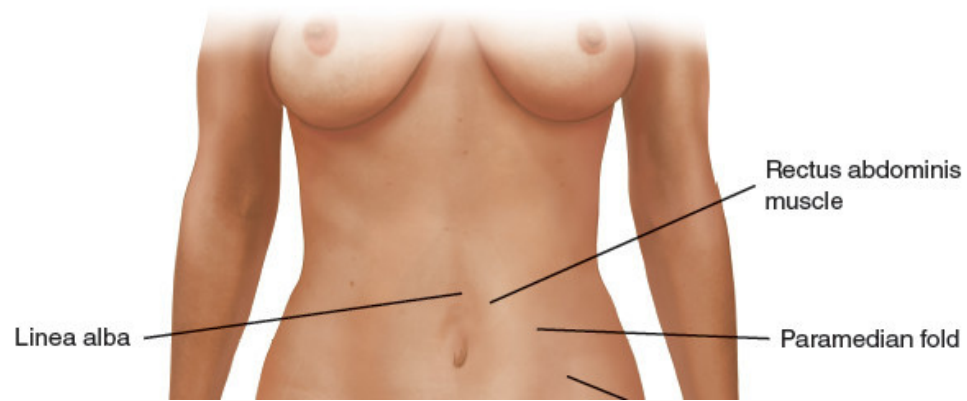
Surgical anatomy

Quick access

LANDMARKS AND ANATOMIC UNITS OF THE ABDOMEN|SKIN AND SUBCUTANEOUS ANATOMY|BLOOD SUPPLY|SENSITIVE INNERVATION|LYMPHATIC SYSTEM|MYOAPONEUROTIC ANATOMY|THE UMBILICUS

LANDMARKS AND ANATOMIC UNITS OF THE ABDOMEN

Anatomic units are areas that must be respected during abdominoplasty. The anatomic units of the abdomen are the areas limited by natural skin depressions and folds. On the limits of these areas, there are attachments, depressions, bone projections, and anatomic structures that should be preserved and highlighted during surgery. These landmarks serve as guidelines to orient the surgeon in creating aesthetic contours, or restoring these details in patients who once had them.



Abdominoplasty

Surgical anatomy

Technique

Complications

Videos

Surgical steps

ALL

» High lateral tension (21 p.)

From: Aly et al.: The Art of Body Contouring: A Comprehensive Approach (2017)

» Reverse (9 p.)

From: Aly et al.: The Art of Body Contouring: A Comprehensive Approach (2017)

» Belt lipectomy (24 p.)

From: Nahai: The Art of Aesthetic Surgery: Principles & Techniques (2010)

» Mini (14 p.)

From: Aly et al.: The Art of Body Contouring: A Comprehensive Approach (2017)

» Fleur-de-Lys (37 p.)

From: Nahai: The Art of Aesthetic Surgery: Principles & Techniques (2010)

+ Limited Abdominoplasty

Comprehensive Abdominoplasty: High Lateral Tension Abdominoplasty With Complementary Fleur-de-Lis and Reverse Techniques

Evolution of the Modern Abdominoplasty

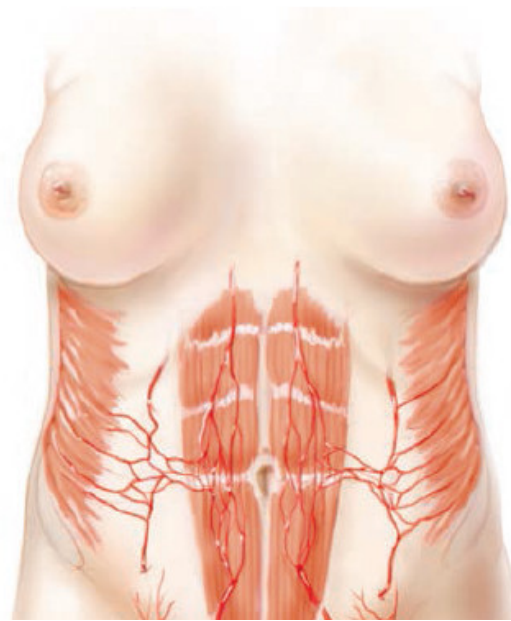
+ The High Lateral Tension Abdominoplasty: A "2.0" Version**+** Fleur-de-Lis Abdominoplasty**+** Reverse Abdominoplasty**+** Results

Concluding Thoughts

Annotated Bibliography

Suggested Readings

Abdominoplasty|Results|Concluding Thoughts|Annotated Bibliography|Suggested Readings



Abdominoplasty

Surgical anatomy

Technique

Complications

Videos

Surgical steps

Source: [CHAPTER 30 Abdominoplasty](#). In: [Cohen M, Thaller S, ed. The Unfavorable Result in Plastic Surgery: Avoidance and Treatment](#). 4th Edition. Thieme; 2018. doi:10.1055/b-005-143642

CHAPTER 30 Abdominoplasty

Avoiding Unfavorable Results and Complications in Abdominoplasty

Primary Goals

- Removal of Excess Soft Tissue
- Correction of the Rectus Diastasis

Secondary Goals

- Scar Placement and Quality
- Umbilicus

Managing Unfavorable Results and Complications in Abdominoplasty

- Seroma and Pseudobursa
- Cellulitis and Deeper Infection
- Flap Viability: Ischemia and Necrosis
- Bleeding and Clotting
- Patient Satisfaction

Conclusion

References

SECTION IV Aesthetic Surgery > CHAPTER 30 Abdominoplasty

A  A

Avoiding unfavorable results

Joseph P. Hunstad and Daniel J. Krochmal

Quick access

[Avoiding Unfavorable Results and Complications in Abdominoplasty](#)|[Managing Unfavorable Results and Complications in Abdominoplasty](#)|[Conclusion](#)|[References](#)

The primary aims of abdominoplasty are restoration of a more ideal abdominal wall contour and removal of excess abdominal skin and soft tissue. Laudable goals of this procedure are to obtain an abdomen that is thin, tight, and flat. If a surgeon accomplishes these objectives, while achieving a relatively inconspicuous scar, an aesthetically pleasing umbilicus, and a complication-free recovery, a patient is usually quite satisfied with the overall result. If any of these goals are not obtained, the result may be unfavorable.

The “unfavorable” aesthetic results in abdominoplasty are usually correctable with revision procedures. With regard to actual complications, the more common ones are typically minor in nature and management is straightforward. The possible severe complications, including fatal pulmonary embolus, necrosis of the abdominal wall skin and soft tissues, and life-threatening infection, are rare.¹ This chapter presents prevention concepts for the more common complications and the unusual challenging complications, along with their management. Also discussed are some tips and tricks that have resulted in enhanced outcomes in our hands.

Avoiding Unfavorable Results and Complications in Abdominoplasty

The ideal patient for an abdominoplasty is an otherwise healthy, nonsmoking patient with a normal body mass index, a lax abdominal wall with rectus diastasis, and excess abdominal skin. Patients that are at higher risk for complications or a suboptimal result include those who are morbidly obese (visceral fat precludes a tight plication), have lung disease including severe chronic obstructive pulmonary disease (muscle plication will limit lung excursion), are currently smoking

Abdominoplasty

Surgical anatomy

Technique

Complications

Videos

Surgical steps

ALL

» Abdominoplasty overview (1 p.)

From: Aly et al.: The Art of Body Contouring: A Comprehensive Approach (2017)

» Circumferential (1 p.)

From: Cohen et al.: The Unfavorable Result in Plastic Surgery: Avoidance and Treatment (2018)

» Reverse (1 p.)

From: Nahai: The Art of Aesthetic Surgery: Principles & Techniques (2010)

» High lateral tension (1 p.)

From: Nahai: The Art of Aesthetic Surgery: Principles & Techniques (2010)

» Endoscopic (1 p.)

» Belt lipectomy (1 p.)

From: Hoschander et al.: Operative Procedures in Plastic, Aesthetic and Reconstructive Surgery (2015)

» Mini liposuction (1 p.)

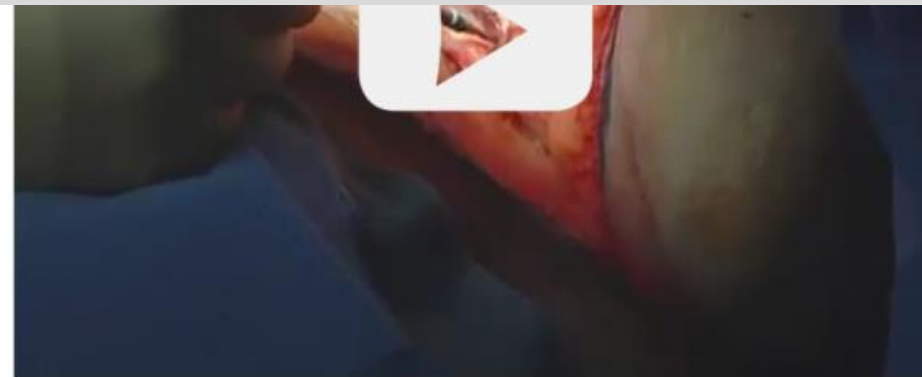
From: Aly et al.: The Art of Body Contouring: A Comprehensive Approach (2017)

» Fleur-de-Lys (1 p.)

From: Nahai: The Art of Aesthetic Surgery: Principles & Techniques (2010)

» Circumferential (1 p.)

From: Strauch et al.: Encyclopedia of Body Sculpting after Massive Weight Loss (2010)



[Clip 1, Chapter 10] Circumferential Abdominoplasty

Source:

Accompanying Videos. In: Strauch B, Herman C, ed. Encyclopedia of Body Sculpting after Massive

Abdominoplasty

Surgical anatomy

Technique

Complications

Videos

Surgical steps

Source: [Abdominoplasty, Panniculectomy, and Belt Lipectomy](#). In: [Hoschander A, Salgado C, Kassira W](#) et al., ed. [Plastic, Aesthetic and Reconstructive Surgery](#). 1st Edition. Thieme; 2016.

Abdominoplasty, Panniculectomy, and Belt Lipectomy

Preoperative Markings

Intraoperative Details

Postoperative Care

Surgical Steps In Plastic Surgery > Abdominoplasty, Panniculectomy, and Belt Lipectomy

Abdominoplasty

Quick access

[Preoperative Markings](#)|[Intraoperative Details](#)|[Postoperative Care](#)

Preoperative Markings

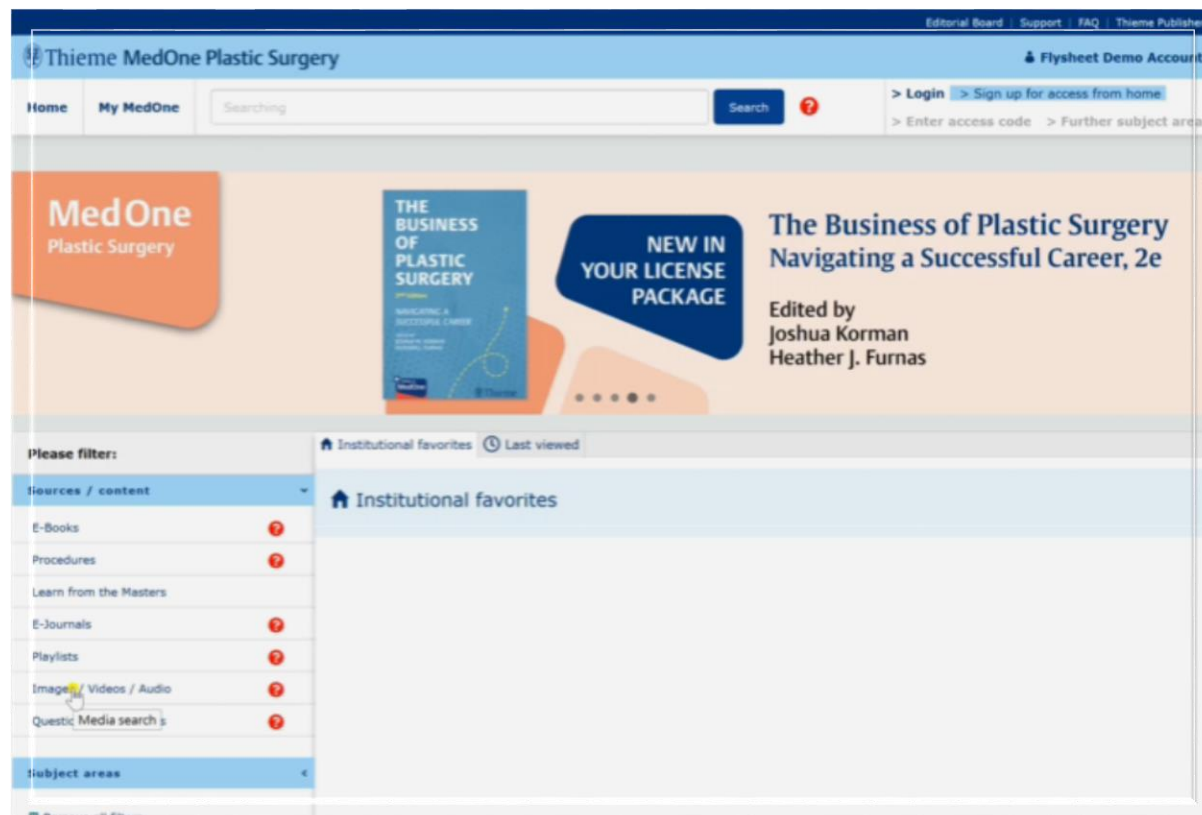
1. The patient should be marked in the standing position in the preoperative holding area.
2. Midaxillary lines and a horizontal waistline should be marked to ensure a symmetrical outcome.
3. For the lower border of the resection, the suprapubic line above the mons pubis is extended laterally in the groin crease. This line must be greater than 5 to 7 cm, superior to the vulvar commissure. From there, lines are extended toward the anterior superior iliac spine (ASIS) to stay within the bikini line.
4. An estimate of the superior border of resection may be marked preoperatively. However, an exact superior border of the resection must be drawn intraoperatively once the flap has been raised, the umbilical stalk freed, and the patient positioned properly to determine the appropriate amount of the resection.

Intraoperative Details

1. Incise the inferior elliptical border using a #10 scalpel. Extend the incision through the dermis with monopolar electrocautery on the pure cut setting, leaving the majority of dermis on the lower skin flap.

多媒體檔案

- 可於欄位以關鍵字檢索多媒體資料
- 可篩選資料為圖片或影片類型
- 游標移至圖片時會出現註解及出處
- 可僅陳列圖片也可以將註解出處隨圖列出
- 點選圖片後，可看到所有該圖所在篇節內所有圖片，點選需要的圖片後可點選右上方輸出為PPT檔案，則可將圖片連同參考資源一併匯出



多媒體檔案：可篩選資料為圖片或影片類型

Please filter: **Audio/Image/Video** Date Relevance

Sources / content Show selection Please select ×

- E-Books ?
- E-Journals ?
- Playlists ?
- Images / Videos / Audio** ?
- Questions and Answers ?

Subject areas <

Remove all filters

Image Video

Fig. 63.15 Rhinoplasty worksheet for case 2.

Fig. 61.28 The goals of rhinoplasty in a patient of African desc...

Video 17.1 Rhinoplasty: Part 1.

Fig. 60.1 The process of successful rhinoplasty can be broken do...

多媒體檔案：游標移至圖片時會出現註解及出處，並提供圖片比較功能

Editorial Board | Support | FAQ | Librarians | Thieme Publishers

Thieme MedOne Plastic Surgery Flysheet Demo Account

Home My MedOne ?

> Login > Sign up for access from home
> Enter access code > Further subject areas

Your search: x rhinoplasty

Your filters: x Media x Image

Please filter: Image Date Relevance


Sources / content Images / Videos / Audio 7,482 results for "rhinoplasty"

- E-Books ?
- E-Journals ?
- Playlists ?
- Images / Videos / Audio** ?
- Questions and Answers ?

Subject areas <


Remove all filters

Fig. 8 profile pres...




The Art of Aesthetic Surgery: Principles & Techniques

Fig. 63.15 Rhinoplasty worksheet for case 2.



Source: Surgical Steps. In: Nahai F, Nahai F, ed. The Art of Aesthetic Surgery: Principles & Techniques. 3rd Edition. Thieme; 2020. doi:10.1055/b000000333

goals of patient of






Analysis

Getting it right

Planning Execution

Fig. 60.1 The process of successful rhinoplasty can be broken do...



Home

My MedOne

rhinoplasty

Search



> Login > Sign up for access from home

> Enter access code > Further subject areas

Your search: **x rhinoplasty**

Your filters: **x Media** **x Image**

Please filter:

Image

Date

Relevance

Sources / content

E-Books



E-Journals



Playlists



Images / Videos / Audio



Questions and Answers



Subject areas

Remove all filters

Images / Videos / Audio 7,482 results for "rhinoplasty"

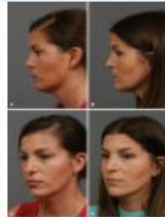

Fig. 8 (A) Preoperative profile view of patient pres...

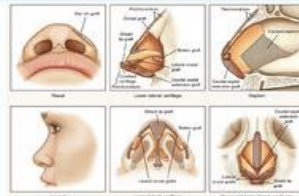


Fig. 63.15 Rhinoplasty worksheet for case 2.

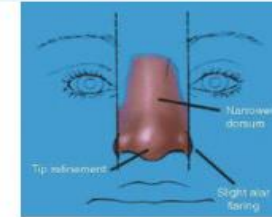


Fig. 61.28 The goals of rhinoplasty in a patient of African desc...

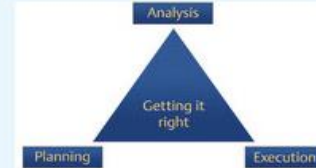

Fig. 60.1 The process of successful rhinoplasty can be broken do...

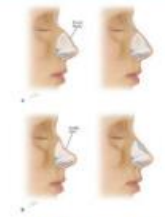


Fig. 51.1 dorsal hump straightening rhinoplasty dorsal hump s...

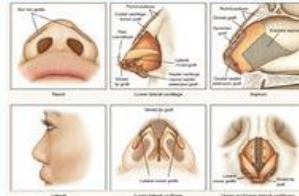


Fig. 63.10 Rhinoplasty worksheet for case 1.

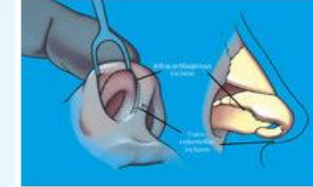


Fig. 1 Stair-step transcolumellar incision with infracartilagin...

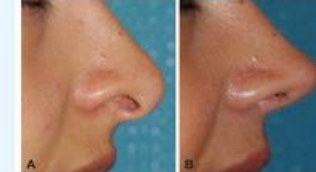

Fig. 7 Before and after profile comparison of patient ...

Compare images

Home

My MedOne

Searching

Search

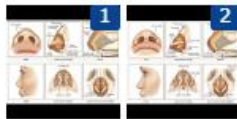

> Login > Sign up for access from home

> Enter access code > Further subject areas

Image comparison

SELECTED FOR COMPARISON:



+
-
↺
↻
1:1
+

 Nasal	 Lower lateral cartilage	 Septum
 Lateral	 Lower lateral cartilage	 Upper and lower lateral cartilages

+
-
↺
↻
1:1
+

 Nasal	 Lower lateral cartilage	 Septum
 Lateral	 Lower lateral cartilage	 Upper and lower lateral cartilages

多媒體檔案：點選圖片後，可看到所有該圖所在篇節內所有圖片，勾選需要的圖片後可點選右上方輸出為PPT檔案，則可將圖片連同參考資源一併匯出

Editorial Board | Support | FAQ | Librarians | Thieme Publishers

Thieme MedOne Plastic Surgery Flysheet Demo Account

Home My MedOne

Searching in Media

Search
?

[> Login](#)
[> Sign up for access from home](#)

[> Enter access code](#)
[> Further subject areas](#)

登入
ebook_cs_11318345_cs15255 (1) - PowerPoint

檔案 常用 iSlide 插入 設計 轉場 動畫 投影片放映 校閱 檢視 說明 ACROBAT 告訴我您想做什么

1
2
3
4
5

16
15
14
13
12
11
10
9
8
7
6
5
4
3
2
1
0
1
2
3
4
5
6
7
8
9
10
11
12
13
14
15
16

Fig. 63.15 Rhinoplasty worksheet for case 2.

Source: [Surgical Steps](#). In: [Nahai F, Nahai F, ed. The Art of Aesthetic Surgery: Principles & Techniques](#). 3rd Edition. Thieme; 2020. doi:10.1055/b000000333

Fair Use/Copyright Exception Disclaimer:
The user is authorized to download select contents of this product for classroom, non-commercial use only.
No part of the contents may be reproduced, altered, posted, or distributed, whether for free or for a fee, to another party unless explicitly authorized by law.

Date of export: 02.25.2021 © 2021 Thieme

Thieme MedOne

Print
PPT
Chat
Star
投影片 1 / 5
中文 (台灣)

≡ 備忘錄
🗨 註解
🏠
📄
🖨
🔍
+ 119%

Home

My MedOne

Searching in Media

Search



> Login

> Sign up for access from home

> Enter access code

> Further subject areas



MODALITY All

AUDIO/IMAGE/VIDEO

All

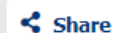Image

Video



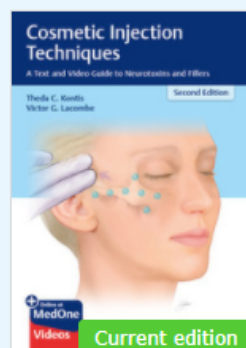- ✓ 循環播放(L)
- ✓ 顯示控制介面(C)
- 在新分頁中開啟影片(O)
- 將影片另存為(M)... Ctrl + S
- 複製影片位址(O)
- 子母畫面
- 投放(C)...
- 檢查(N) Ctrl + Shift + I

▶ 0:51 / 3:24



Theda C. Kontis, Victor G. Lacombe

Cosmetic Injection Techniques: A Text and Video Guide to Neurotoxins and Fillers



Current edition



Source: In: [Kontis T, Lacombe V, ed.](#)
2nd Edition. Thieme; 2019.
doi:10.1055/b-006-160134

Show videos

Content Images Hits

- + Introduction to Injectables
- + Introduction to Neurotoxins
- + Neurotoxin Injection Techniques
- + Introduction to Fillers
- **Filler Injection Techniques**

Filler Injection for Nasolabial Folds

Filler Injection with Polymethyl Methacrylate (Bellafill)

Search within this E-Book



Filler Injection Techniques > Filler Injection for Nonsurgical Rhinoplasty



Filler Injection for Nonsurgical Rhinoplasty

+ Playlist

Quick access

[Indications](#)|[Anatomic Considerations](#)|[Injection Technique](#)|[Precautions](#)|[Post-Injection Instructions](#)|[Risks](#)|[Pearls of Injection](#)|[Additional Reading](#)

Difficulty: ●●●●

Patient Satisfaction: ●●●

Risk: ●●

Indications

Because the nose occupies the center of the face, even mild asymmetries can be quite striking. Rhinoplasty surgery is not always a perfect procedure, and postsurgical defects can be difficult to correct. As a result, the use of fillers in small quantities to treat specific nasal deformities has become a way to fine-tune postsurgical noses. In addition, in some patients who refuse surgery or who are not surgical candidates, a nonsurgical approach to their nasal concerns may be possible by the use of filling agents.

Anatomic Considerations

Home

My MedOne

Searching in Media

Search



> Login

> Sign up for access from home

> Enter access code

> Further subject areas

Your filters:

Media

Cosmetic Injection Techniques: A Text and Video Guide to Neurotoxins and Fillers

Video



Please filter:

Video

Date

Relevance



Sources / content

E-Books



Playlists



Images / Videos / Audio



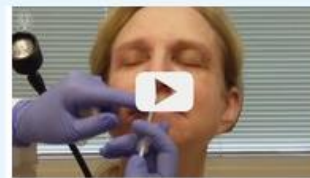Questions and Answers



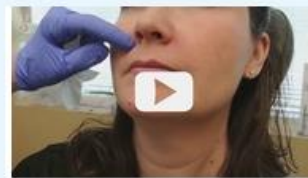Subject areas

Remove all filters

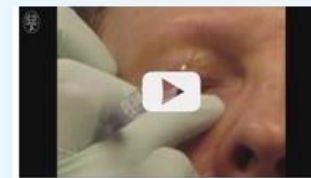109 results for your search with filters "Media", "Cosmetic Injection Techniques: A Text and Video Guide to Neurotoxins and Fillers", "video"



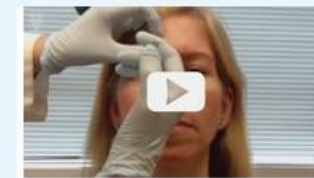[Video 13.1] Neurotoxin Injection for Nasal Tip Lift



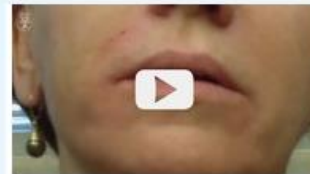[Video 18.1] Neurotoxin Injection for Gummy Smile



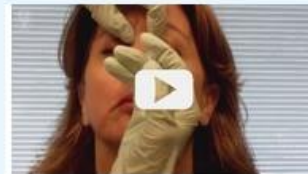[Video 47.1] Filler Injection for Tear Trough Deformity and Che...



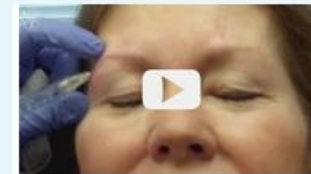[Video 6.1] Neurotoxin Injection for Glabellar Frown Lines



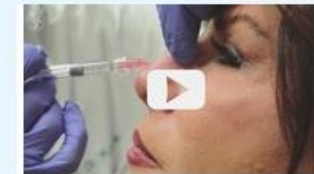[Video 38.4] Filler Injection for Nasolabial Folds, Marionette ...



[Video 19.2] Neurotoxin Injection for Glabellar Frown Lines and...



[Video 49.1] Filler Injection for Lateral Brow Lift



[Video 51.1] Filler Injection for Non-Surgical Rhinoplasty



Compare images

目錄清單-MedOne提供客製目錄功能以便您為自己或單位儲存最愛的內容以便日後可直接查看

- 製作個人目錄後只要登入帳號就可直接看到“My Playlists”。也可以製作多個不同的目錄
- 點選**Create**，於視窗中輸入客製的目錄名稱、選擇主題領域，儲存後就可以了
- 點選任何內容上方黃色星號就可加入清單。於視窗中選擇該內容所屬目錄，點選最下方“apply changes”
- 可於清單內容中設定該篇是否要分享
- 也可以將網路資源或個人檔案上傳至MedOne的目錄清單



Home

My MedOne

Searching

Search



> Login > Sign up for access from home

> Enter access code > Further subject areas

Your filters: Public playlists

Please filter:

Sources / content ▾

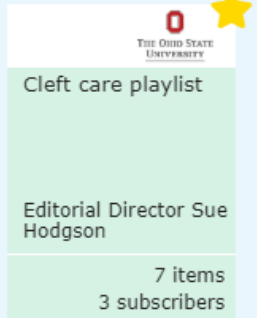
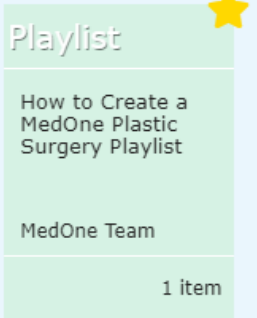

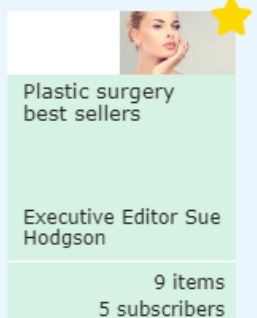
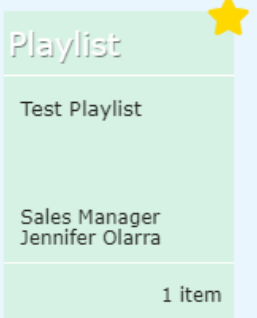
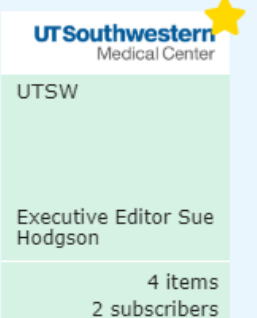
- E-Books ?
- Procedures ?
- Learn from the Masters
- E-Journals ?
- Playlists** ?
- Images / Videos / Audio ?
- Questions and Answers ?

Subject areas <

Remove all filters

Public playlists Playlist Collections

Please apply filter...

	Name	Date updated
Create new playlist		
 <p>Cleft care playlist</p> <p>Editorial Director Sue Hodgson</p> <p>7 items 3 subscribers</p>	 <p>Playlist</p> <p>How to Create a MedOne Plastic Surgery Playlist</p> <p>MedOne Team</p> <p>1 item</p>	 <p>MedOne Plastic Surgery</p> <p>FREE ACCESS</p>
 <p>Plastic surgery best sellers</p> <p>Executive Editor Sue Hodgson</p> <p>9 items 5 subscribers</p>	 <p>Playlist</p> <p>Test Playlist</p> <p>Sales Manager Jennifer Olarra</p> <p>1 item</p>	 <p>UTSouthwestern Medical Center</p> <p>UTSW</p> <p>Executive Editor Sue Hodgson</p> <p>4 items 2 subscribers</p>
No additional entries available		

Home

My MedOne

Searching

Search

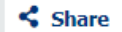

> Login > Sign up for access from home

> Enter access code > Further subject areas

Playlist created by: Editorial Director Sue Hodgson

Cleft care playlist Plast



Cleft care playlist

Editorial Director Sue Hodgson

7 items
3 subscribers

Image view

Search within this Playlist

Cleft care playlist



Joseph Losee

Content Collection

Joseph E. Losee

Comment: Cleft palate expert with videos



Video

Useful video

Source: Accompanying Videos. In: Bentz M, Bauer B, Zuker R, ed. Principles & Practice of Pediatric Plastic Surgery. 2nd Edition. Thieme; 2016. doi:10.1055/b-006-161029

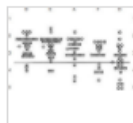


Chapter

Part I Fundamentals of Cleft Care

Part I Fundamentals of Cleft Care

Source: Part I Fundamentals of Cleft Care. In: Losee J, Kirschner R, Smith D et al., ed. Comprehensive Cleft Care. Family Edition.. 1st Edition. Thieme; 2015. doi:10.1055/b-006-160993



Chapter

Part I Fundamentals

Part I Fundamentals

Source: Part I Fundamentals. In: Losee J, Kirschner R, ed. Comprehensive Cleft Care. 2nd Edition. Thieme; 2015. doi:10.1055/b-004-140252



Chapter

Part VIII Primary Cleft Lip and Palate Repair

Part VIII Primary Cleft Lip and Palate Repair

Source: Part VIII Primary Cleft Lip and Palate Repair. In: Losee J, Kirschner R, ed. Comprehensive Cleft Care. 2nd Edition.

[S. Douglas Steinbrech](#)

Male Aesthetic Plastic Surgery

D.S. STEINBRECH



Source: In: [Steinbrech S](#), ed. 1st Edition. Thieme; 2020.
doi:10.1055/b-006-163729

[Show videos](#)[Content](#) [Images](#) [Hits](#)[Steps for Male Rhinoplasty— Expert Technique](#)[Male Rhinoplasty Considerations by Anatomical Regions](#)[Steps for Male Rhinoplasty](#)[CHAPTER 18 Male Rhinoplasty: Expert Technique](#)[CHAPTER 17 Male Rhinoplasty](#)[Technological Advances in Virtual Surgery](#)[Management of Complications](#)[CHAPTER 3 Virtual Surgery](#)[CHAPTER 12 Chin Augmentation](#)[Trends in Male Preferences for Aesthetics Surgery](#)

rhinoplasty



Part I The Male-Oriented Office



Part I The Male-Oriented Office

[+ Playlist](#)

Quick access

[CHAPTER 1 Marketing Aesthetic Procedures to Men](#)|[CHAPTER 2 Photography for the Male Aesthetic Patient](#)|[CHAPTER 3 Virtual Surgery](#)

CHAPTER 1 Marketing Aesthetic Procedures to Men

Thomas F. La Vecchia and Douglas S. Steinbrech

Summary

As an increasing number of men are undergoing aesthetic procedures, aesthetic surgery centers need to familiarize themselves with proven techniques for marketing to the male client. This chapter covers general marketing techniques, such as brand positioning and content generation, as well as how to develop a revenue-generating social media presence.

Introduction

X Factor Media was approached by Dr. Douglas S. Steinbrech in late 2013 with a new initiative. He wanted to roll out a website dedicated to male aesthetic surgery. At the time, we were a bit skeptical. Our research showed that men only constituted for roughly 9% of all aesthetic procedures in 2012. We were tasked with creating a website or an online resource (more or less). Male Plastic Surgery New York was born (www.MalePlasticSurgeryNewYork.com) ([Fig. 1.1](#)).

Our Approach: Build the Platform

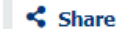X Factor Media started the campaign with reviewing the top procedures for men. According to the American Society for Aesthetic Plastic Surgery (ASAPS),¹ they are:

- ▶ Liposuction.
- ▶ Gynecomastia (removal of breast tissue).
- ▶ Eyelid surgery.
- ▶ **Rhinoplasty.**
- ▶ Facelift.

[Home](#)[My MedOne](#)

Searching in E-Journals

Search

[> Login](#) [> Sign up for access from home](#)[> Enter access code](#) [> Further subject areas](#)[« Back to overview](#)

Journal of Reconstructive Microsurgery 02/2021

Journal of Reconstructive
Microsurgery 02/2021

Archive

[Content](#) [Images](#) [Hits](#)

Review Article

Anatomy, Exposure, and
Preparation of Recipient Vessels in
Microsurgical Head and Neck
Reconstruction

Anatomy

Vessel Selection

Exposure Techniques

Anterior Triangle (External
Carotid Branches, Internal
Jugular System, and External
Jugular System)Submandibular (Facial Artery
and Facial Vein)

Search within this E-Journal



Journal of Reconstructive Microsurgery 2021; 37(02): 097 - 110

DOI: 10.1055/s-0040-1715644

Review Article

Xu, Hope¹; Jazayeri, Leila²; Matros, Evan³; Henderson, Peter W.¹Anatomy, Exposure, and Preparation of Recipient Vessels in
Microsurgical Head and Neck Reconstruction [+ Playlist](#)¹ Division of Plastic and Reconstructive Surgery, Department of Surgery, Icahn School of Medicine at Mount Sinai, New York, New York² Department of Plastic Surgery, Kaiser Permanente, San Leandro Medical Center, San Leandro, California³ Plastic and Reconstructive Surgical Service, Memorial Sloan Kettering Cancer Center, New York, New York

Quick access

Anatomy|Vessel Selection|Exposure Techniques|Anterior Triangle (External Carotid Branches, Internal Jugular System, and External Jugular System)|Submandibular (Facial Artery and Facial Vein)|Intraoral (Facial Artery and Facial Vein)|Posterior Triangle (Transverse Cervical Artery and Transverse Cervical Vein)|Preauricular (Superficial Temporal Artery and Superficial Temporal Vein)|Chest (Internal Mammary Artery and Internal Mammary Vein[s])|Arm/Infraclavicular Region (Cephalic Vein)|Conclusion|References

Abstract

Successful microvascular reconstruction of head and neck defects requires the ability to safely identify, isolate, and utilize recipient vessels. To date, however, a comprehensive review of the anatomy and techniques relevant to the available anatomic regions has not been undertaken. This review covers the relevant clinical anatomy of the anterior triangle, posterior triangle, submandibular region, intraoral region, preauricular region, chest, and arm, taking particular care to highlight the structures that are crucial to identify while performing each dissection. Finally, a step-by-step technique for safely dissecting the recipient

Abdominoplasty

Surgical anatomy

Technique

Complications

Videos

Surgical steps

Source: [CHAPTER 30 Abdominoplasty](#). In: [Cohen M, Thaller S, ed. The Unfavorable Result in Plastic Surgery: Avoidance and Treatment](#). 4th Edition. Thieme; 2018. doi:10.1055/b-005-143642

CHAPTER 30 Abdominoplasty

Avoiding Unfavorable Results and Complications in Abdominoplasty

Primary Goals

- Removal of Excess Soft Tissue
- Correction of the Rectus Diastasis

Secondary Goals

- Scar Placement and Quality
- Umbilicus

Managing Unfavorable Results and Complications in Abdominoplasty

- Seroma and Pseudobursa
- Cellulitis and Deeper Infection
- Flap Viability: Ischemia and Necrosis
- Bleeding and Clotting
- Patient Satisfaction

Conclusion

References

SECTION IV Aesthetic Surgery > CHAPTER 30 Abdominoplasty



Avoiding unfavorable results

Joseph P. Hunstad and Daniel J. Krochmal

Quick access

[Avoiding Unfavorable Results and Complications in Abdominoplasty](#)|[Managing Unfavorable Results and Complications in Abdominoplasty](#)|[Conclusion](#)|[References](#)

The primary aims of abdominoplasty are restoration of a more ideal abdominal wall contour and removal of excess abdominal skin and soft tissue. Laudable goals of this procedure are to obtain an abdomen that is thin, tight, and flat. If a surgeon accomplishes these objectives, while achieving a relatively inconspicuous scar, an aesthetically pleasing umbilicus, and a complication-free recovery, a patient is usually quite satisfied with the overall result. If any of these goals are not obtained, the result may be unfavorable.

The “unfavorable” aesthetic results in abdominoplasty are usually correctable with revision procedures. With regard to actual complications, the more common ones are typically minor in nature and management is straightforward. The possible severe complications, including fatal pulmonary embolus, necrosis of the abdominal wall skin and soft tissues, and life-threatening infection, are rare.¹ This chapter presents prevention concepts for the more common complications and the unusual challenging complications, along with their management. Also discussed are some tips and tricks that have resulted in enhanced outcomes in our hands.

Avoiding Unfavorable Results and Complications in Abdominoplasty

The ideal patient for an abdominoplasty is an otherwise healthy, nonsmoking patient with a normal body mass index, a lax abdominal wall with rectus diastasis, and excess abdominal skin. Patients that are at higher risk for complications or a suboptimal result include those who are morbidly obese (visceral fat precludes a tight plication), have lung disease including severe chronic obstructive pulmonary disease (muscle plication will limit lung excursion), are currently smoking

訓練中心：使用問題、答案和解釋的資料庫進行有效的學習。

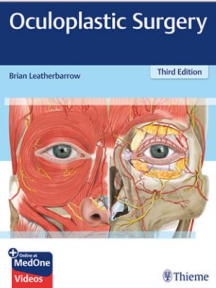
Thieme MedOne Plastic Surgery
Flysheet Demo Account

Home
My MedOne

Search

?

[> Login](#)
[> Sign up for access from home](#)
[> Enter access code](#)
[> Further subject areas](#)



NEW IN YOUR LICENSE PACKAGE

Oculoplastic Surgery

Third Edition

Brian Leatherbarrow

MedOne

Plastic Surgery

Please filter:

Sources / content


- E-Books ?
- Procedures ?
- Learn from the Masters
- E-Journals ?
- Playlists ?
- Images / Videos / Audio ?
- Questions and Answers ?

Subject areas


Remove all filters

🏠 Institutional favorites
🕒 Last viewed

🕒 Last viewed



Fu-Chan Wei



Al Aly

Plast

Procedures:
Aesthetic surgery

» Hair transplantation

Plastic surgery best sellers

Executive Editor Sue Hodgson

9 items
4 subscribers

UTSouthwestern Medical Center

UTSW

Executive Editor Sue Hodgson

4 items
2 subscribers

61

建立複習或考試：通過從“選擇類型”選單中進行選擇來創建複習課程或練習考試。此選擇確定您在完成“問題”時是否會看到答案。

Create customized board review exam sessions.
Check your statistics and see how you performed.

Pool
1045
Questions

+ Create session Recent sessions Statistics

Choose type

Review session Practice exam

Number of questions 40

Session time (minutes) 60

Time per question (minutes) 1.5

Essentials of plastic surgery Q+A

Select: Essentials of plastic surgery Q+A

Show questions

Selected before Not selected before

With images Without images

Previously answered correctly Previously answered incorrectly

Review session, 40 Questions **Start session**

複習課程：通過複習課程，您可以查看每個問題的正確答案以及解釋。選擇答案後，單擊“Submit answer”按鈕，正確答案將以綠色顯示。錯誤答案以紅色突出顯示。單擊“Further Information”選項，可以查看與該問題有關的其他資訊。**Extent Session**可以增加時間。

練習考試：練習考試僅顯示問題和多項選擇答案。當您選擇“結束會話”或時間到期時，考試結束。考試完成後，方可通過正確的答案和解釋進行複習。

The screenshot displays a quiz interface with the following elements:

- Question Section:** Labeled "Question 5 of 10".
- Answer Section:** Lists five options:
 - A. Unilateral coronal
 - B. Metopic (Selected, indicated by a green checkmark and a red arrow)
 - C. Lambdoid (Incorrect, indicated by a red bar and a red arrow)
 - D. Sagittal
 - E. Bilateral coronal
- Buttons:** "Submit answer" and "Show correct answer".
- Further information:** A dropdown menu showing text: "The appearance described is known as *trigonocephaly*. This is caused by premature the metopic suture. A spectrum of deformities occurs, including bitemporal g, hypotelorism, and bilateral supraorbital retrusion." (A red arrow points to this text).
- Time up Notification:** A modal box titled "Time up" with the message: "Your time is up. You have completed 5 questions out of 10 selected. You can choose to continue this session or finish and start a new one." It includes "Finish Session" and "Extend Session" buttons.
- Bottom Navigation:** "Finish Session", "Previous", "5 / 10", and "Next" buttons.

設定時間：選擇類型後，您可以決定問題的數量以及所需的時間。只需將光標放在要調整的字段中，然後輸入所需的值即可。

每個問題的時間是自動計算的。

Number of questions	40	Session time (minutes)	60	Time per question (minutes)	1.5
---------------------	----	------------------------	----	-----------------------------	-----


確定問題數量和會話時長後，可以通過從下面顯示框中來過濾問題。

Essentials of plastic surgery Q+A

Select: Essentials of plastic surgery Q+A

選擇篩選項目後，會彈出一個窗口，顯示其中的選項：

Select: Essentials of plastic surgery Q+A ×

Essentials of plastic surgery Q+A  Select all

- Aesthetic surgery
- Fundamentals and basics in plastic surgery
- Plastic breast surgery
- Plastic surgery of the hand, wrist and upper extremity
- Plastic surgery of the head and neck
- Plastic surgery of the skin and soft tissue
- Plastic surgery of the trunk and lower extremity

Cancel Finish selection

問題可能會由於諸如圖像的存在或您之前是否看過問題而被進一步過濾掉。

Show questions

Selected before

Not selected before

With images

Without images

Previously answered correctly

Previously answered incorrectly

所有篩選完成後，點擊 **“Start Session”** 按鈕開始。

Review session, 40 Questions

Start session

回答問題時，右上角會顯示一個計時器，以幫助您跟踪處理問題的時間。點擊“Finish Session”後，將要求您確認要結束會話。

The screenshot shows a quiz interface titled "Review session June 20, 2019" with a timer at 00:59:50. The question is: "Which one of the following statements is true of the process of wound healing?". The answer options are:

- A. It is comprised of five key phases.
- B. Vasodilatation is the initial response after injury.
- C. Each of the key phases are distinct entities.
- D. Each of the phases are of similar duration.
- E. The wound healing process differs in fetal tissue.

 Below the answers are buttons for "Submit answer" and "Show correct answer". A "Further information" section is partially visible. At the bottom right, there is a "Finish Session" button and navigation controls for "Previous", "1 / 40", and "Next". A red arrow points from the "Further information" section towards the "Finish Session" button.

The dialog box is titled "Finish Session" and contains the text: "Are you sure that you want to finish your session?". At the bottom, there are two buttons: "Finish Session" and "Cancel".

完成後，您將收到回覆的詳細資料，包括；完成所需的時間和正確和錯誤回答的問題數量。

Congratulations, you have reached the end
of the review test ×

You took	14 minutes and 12 seconds
Correctly answered questions	3
Incorrectly answered questions	7
Unanswered questions	0
Answered questions	10

Repeat session

Create new session

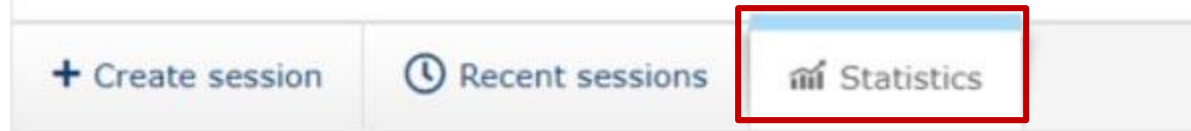
最近的測驗/練習：您的複習/考試將被保存以供將來查看。

[+ Create session](#)
[Recent sessions](#)
[Statistics](#)

Filter by type: All sessions
Sort by date: Newest first

Review session June 19, 2019 OPEN Created: 19.06.2019, 15:27, 10 questions		5 of 10 ✓ 1 ✗ 4		
Review session January 17, 2019 OPEN Created: 17.01.2019, 10:57, 16 questions		15 of 16 ✓ 4 ✗ 11		
Review session January 22, 2019 OPEN Created: 22.01.2019, 16:53, 5 questions		2 of 5 ✓ 0 ✗ 2		

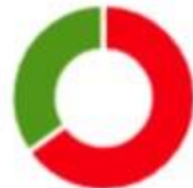統計數據：統計頁面可讓您評估學習的有效性，並通過複習課程和練習考試來記錄您的成長情況。



My Statistics

Review Session Completed:	8
Practice Tests Completed:	0
Total Questions Answered:	158

Click on graphs below for more detail



55 out of 158 Answers correct (35 %)

從圖書館電子資源查詢系統進入使用



Chang Gung Medical Foundation
長庚醫療財團法人 電子資源查詢系統
E-Resources Gateway 林口/桃園圖書館

資料庫(Database) | 電子期刊(E-Journals) | 電子書(E-Books) | 網路資源(Web Resources) | 個人化服務

首頁 | 最新消息 | 常見問題 | 登出 (Logout)

資源瀏覽

- 題名排列
- 主題排列
- 出版商排列
- 試用資源
- 免費資源
- 新到資料庫
- 熱門點閱
- 熱門收藏
- 熱門推薦

【資源查詢】

medone 資源名稱 資料庫 精確檢索 查詢 進階查詢

資料庫: 所有(52筆)
 注音符號: ㄇ ㄛ ㄩ ㄉ ㄥ ㄨ ㄨ ㄨ
 中文筆劃: 4 5 6 10 12 13+
 A to Z瀏覽: A B C D E H I J K L M O P S T U W
 T ->: T H

共 2 筆 每頁筆數 50 GO 第 1 筆

編號 No.	題名 Title	類型 Type	出版平台 Publisher	收錄年代/出版年 Full Text Coverage	其它註記 Other Info.	Web2.0
1	Thieme MedOne Plastic Surgery + 收藏 ★ 推薦 ! 簡介	Ⓛ	Thieme		意見反應	點閱: 250 收藏: 4 推薦: 1
2	Thieme電子書	Ⓛ	Thieme		意見反應	點閱: 1718

查詢結果分類

- 主題
 - 一般醫學(2)
- 資料庫代理商/出版商
 - Thieme(2)

如欲了解更多訊息，請洽飛資得醫學或是拜訪網頁：
<https://medone-neurosurgery.thieme.com>

